

Anti-inflammatory and anti-oxidant efficacy of organum species and honey in a rat model of COPD

Fadime Ovalı ^{1*}, Hüsamettin Vatansev ², Hakan Vatansev ³, Bayram Çolak ⁴, İsmail Harmankaya ⁵

¹ Department of Medical Biochemistry, Institute of Health Sciences, Selçuk University, Konya, Turkey

² Department of Medical Biochemistry, Faculty of Medicine, Selçuk University, Konya, Turkey

³ Department of Food Processing, Meram Vocational School, Necmettin Erbakan University, Konya, Turkey

⁴ Department of General Surgery, Department of Surgical Medical Sciences, Faculty of Medicine, İzmir Bakırçay University, İzmir, Turkey

⁵ Department of Pathology, Faculty of Medicine, Selçuk University, Konya, Turkey

ARTICLE INFO

Article type:

Original

Article history:

Received: Jul 18, 2025

Accepted: Oct 19, 2025

Keywords:

Animal models
Chronic obstructive
Honey
Inflammation
Matrix metalloproteinase 9
Origanum
Oxidative stress
Pulmonary disease
T-Lymphocytes

ABSTRACT

Objective(s): Chronic obstructive Pulmonary Disease (COPD) is a progressive airway condition characterized by chronic inflammation, oxidative stress, and tissue remodeling. Conventional treatments offer limited benefits in halting disease progression, promoting increased interest in natural agents with antioxidant and anti-inflammatory properties. This study aimed to evaluate the therapeutic effects of *Origanum onites* L., *Origanum minutiflorum*, and honey in a rat model of elastase-induced COPD.

Materials and Methods: Thirty-eight female Wistar albino rats were divided into five groups: Control, COPD, *O. onites* L. treatment, *O. minutiflorum* treatment, and honey treatment. COPD was induced via intratracheal porcine pancreatic elastase. Treatments were administered orally for 15 days. Serum levels of IL-1 α , IL-33, and HMGB1, and lung homogenate levels of MMP-9 and TIMP-1 were measured by ELISA. T cell subtypes (CD3⁺, CD4⁺, CD8⁺) were analyzed by flow cytometry. Blood gas parameters were evaluated, and histopathological scoring was performed.

Results: *Origanum onites* L., *O. minutiflorum*, and honey exhibited modulatory effects on inflammatory and oxidative markers. *O. minutiflorum* significantly reduced IL-1 α and IL-33 levels ($P<0.05$) and decreased MMP-9 expression. The honey group showed increased TIMP-1 levels and significantly improved blood oxygenation (pO₂ and sO₂). CD3⁺ and CD8⁺ T cell percentages were significantly higher in the treatment groups compared to the COPD group. Emphysema scores were significantly lower in the honey group ($P<0.05$), and lymphoid aggregates were observed only in the COPD group.

Conclusion: The findings indicate that *Origanum* species and honey may have therapeutic potential for COPD by modulating inflammation, the immune response, and the protease-antiprotease balance. Further molecular and clinical studies are warranted.

► Please cite this article as:

Ovalı F, Vatansev H, Vatansev H, Çolak B, Harmankaya İ. Anti-inflammatory and anti-oxidant efficacy of organum species and honey in a rat model of COPD. Iran J Basic Med Sci 2025; 29:

Introduction

Chronic Obstructive Pulmonary Disease (COPD) is a heterogeneous lung disorder characterized by persistent respiratory symptoms and airflow restriction, imposing a substantial burden on individuals and healthcare systems (1). Its pathogenesis involves chronic inflammation of the small airways, primarily bronchiolitis, accompanied by structural changes such as mucus hypersecretion, luminal obstruction, and tissue destruction. The accumulation of immune cells, including neutrophils, CD8⁺ T lymphocytes, and macrophages, initiates an inflammatory cascade that contributes to tissue remodeling and pulmonary vascular alterations, potentially leading to complications such as pulmonary hypertension and right heart failure (2-4).

Current treatment approaches, including bronchodilators, corticosteroids, and phosphodiesterase-4 inhibitors like roflumilast, aim to relieve symptoms and

reduce exacerbations and mortality risk, although they are often insufficient to halt disease progression (5). As a result, there is growing interest in complementary and herbal therapies with anti-inflammatory and bronchodilatory potential (6).

In recent years, thyme species and their derivatives have gained attention as alternative therapeutic options in inflammatory pulmonary diseases such as COPD. *Origanum onites* L. is a steno-endemic species native to the Eastern Mediterranean region and has been widely used in traditional Turkish medicine, primarily due to its high carvacrol content (7, 8). Its essential oil is rich in oxygenated monoterpenes, with carvacrol and thymol being the primary constituents responsible for its potent antioxidant, anti-inflammatory, and antimicrobial effects (9-11). In addition, the plant contains high levels of phenolic acids such as rosmarinic, caffeic, gallic, and ferulic acids, along

*Corresponding author: Fadime Ovalı. Department of Medical Biochemistry, Institute of Health Sciences, Selçuk University, Konya, Turkey. Tel/ Fax: +90-5444728990, Email: ovali.fadime@gmail.com



© 2026. This work is openly licensed via [CC BY 4.0](https://creativecommons.org/licenses/by/4.0/).

This is an Open Access article distributed under the terms of the Creative Commons Attribution License (<https://creativecommons.org/licenses/by/4.0/>), which permits unrestricted use, distribution, and reproduction in any medium, provided the original work is properly cited.

with flavonoids, all of which contribute to its therapeutic potential (12, 13).

Origanum minutiflorum is an endemic species that grows at high altitudes in the Taurus Mountains of southern Turkey. It has been traditionally used to treat respiratory and gastrointestinal ailments (14). The essential oil of *O. minutiflorum* contains up to 90% carvacrol, making it the richest among *Origanum* species in this compound. It also contains p-cymene and γ -terpinene, which exhibit antimicrobial, antioxidant, anti-inflammatory, and antiproliferative properties (15-17). In prior studies, *Origanum onites* L. and *O. minutiflorum* extracts have been shown to exert anti-inflammatory and antioxidant effects by modulating key cytokines such as IL-1 α and HMGB1, as well as proteolytic enzymes, such as MMP-9, thereby reducing tissue destruction in COPD-like models (12, 16, 17). Similarly, natural honey has been demonstrated to attenuate airway inflammation, improve oxidative balance, and enhance immune regulation in experimental models of asthma and lung injury, largely through its polyphenolic content (18, 19). These findings support the potential role of these natural agents as complementary therapies in inflammatory pulmonary diseases. In this context, the present study aimed to investigate the therapeutic effects of *Origanum onites* L., *O. minutiflorum*, and honey in a rat model of elastase-induced COPD.

Materials and Methods

Plant and honey source

Origanum onites L. was collected from Hadim/Taşkent district of Konya province in Turkey, while *O. minutiflorum* was collected from Hatay/Turkey. The honey samples were obtained from local producers in Muğla/Turkey. Thyme samples were shade-dried and extracted using water. The plant materials used in this study, *O. onites* L. and *O. minutiflorum* O. Schwarz & P.F. Davis, were identified based on their taxonomic and morphological characteristics described in volume 7 of "Flora of Turkey and the East Aegean Islands," on pages 166-167 and 179-180, respectively. Both species are native to Turkey, with *O. minutiflorum* being an endemic species.

Plant extraction

A total of 30 g of each thyme species was extracted with 300 ml of distilled water using a Soxhlet apparatus at 90-95 °C for eight hours. After extraction, solvents were removed using a rotary evaporator, and the extracts were sonicated and transferred to vials. These vials were dried in a water bath for one week.

Chemical analyses

- Volatile oil composition was determined by GC-MS following hydrodistillation.
- Phenolic compounds and organic acids were analyzed using HPLC.
- Antioxidant activity was assessed via the DPPH radical scavenging method.

Animals and experimental groups

Thirty-eight 6-month-old female Wistar Albino rats, weighing approximately 250 g, were used. Female rats were selected for this study due to their more docile nature and lower levels of aggression compared to males. Male rats are known to display territorial and dominance behaviors, which

can lead to increased stress and variability in physiological parameters. These behavioral fluctuations may compromise the consistency of experimental outcomes. In contrast, female rats tend to exhibit more stable social interactions, allowing for a more homogeneous experimental model. For these reasons, female Wistar albino rats were preferred in this study. The sample size was estimated with reference to prior similar studies using elastase-induced COPD models, to ensure sufficient statistical power for detecting differences in biochemical and histopathological parameters. Animals showing signs of infection, injury, or respiratory distress at baseline were excluded. No animals were removed from the study after the experiment began. The primary outcome measure used to justify the sample size was serum IL-1 α concentration, based on its reported sensitivity to reflect inflammatory changes in COPD models in previous studies. Animals were housed under a 12-hour light/dark cycle and randomly assigned into five groups (Figure 1). A permanent cage labeling system was used to ensure accurate identification of groups, and each rat was also individually marked with a non-toxic dye for easy distinction.

- Control (n=6)
- COPD group (Elastase-induced, untreated) (n=8)
- COPD+*O. onites* L. treatment (n=8)
- COPD+*O. minutiflorum* treatment (n=8)
- COPD+honey treatment (n=8)

The COPD model was induced via intratracheal administration of porcine pancreatic elastase (PPE)(Sigma Chemical, St. Louis, MO, USA) at a dose of 55 U/100 g (20). Anesthesia was induced with a combination of xylazine (10 mg/kg) and ketamine (80 mg/kg) to minimize pain and distress during procedures. Blood gas analysis and histopathological examination were used to confirm model induction. Dose selection for *Origanum* extracts was guided by previous studies using aqueous oregano preparations (150-350 mg/kg/day, 14 days) and hydroalcoholic extracts (400 mg/kg/day, 7 days) that showed pulmonary protection (21-23). In addition, *Origanum floribundum*, with a chemical profile similar to our species, was reported to be safe up to 2000 mg/kg in Wistar rats (24). Based on these data, we administered an aqueous extract at 500 mg/kg/day for 15 days.

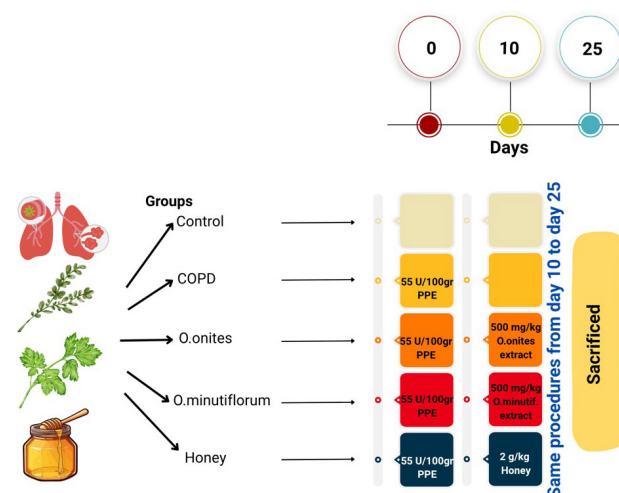


Figure 1. Experimental design and treatment timeline of the study to evaluate the effects of *Origanum* extracts and honey in a porcine pancreatic elastase (PPE) induced chronic obstructive pulmonary disease (COPD) rat model

Honey has been reported to exert anti-diabetic and antioxidant effects in rodent models at doses of about 1-2.5 g/kg. Therefore, we used 2 g/kg/day for 15 days in our study (18, 25).

Histopathological evaluation

Lung tissues were fixed in 10% formalin, stained with hematoxylin and eosin (H&E)(Merck, Germany), and examined under an Olympus BX53 light microscope (Olympus Corporation, Tokyo, Japan). In histopathological evaluation, findings such as emphysema, inflammation, lymphoid accumulation, fibrosis, necrosis, and granuloma formation were scored semiquantitatively, graded from 0 (absent) to 3 (severe), based on their severity and prevalence. The semi-quantitative scoring system for histopathological findings is shown in Table 1.

Biochemical and immunological measurements

COPD was induced in rats via intratracheal administration of PPE. On the 3rd day after induction, venous blood gas analysis was performed in all rats using the tail vein, serving as a pre-treatment reference point. On day 10, one randomly selected rat from the COPD group and one from the control group were sacrificed; cardiac blood was collected for blood gas analysis, and lung tissues were harvested for histopathological confirmation of the COPD model. Typical signs of emphysema and inflammation were observed in the COPD rat, while control lungs appeared normal. Following confirmation, the remaining rats in the treatment groups received *Origanum onites* L., *O. minutiflorum*, or honey by oral gavage for 15 consecutive days. At the end of the treatment period, blood samples were collected from the heart under anesthesia for the final blood gas analysis. Venous blood gas analysis was performed using an ABL9 blood gas analyzer (Radiometer Medical A/S, Denmark). The parameters measured included pH, partial carbon dioxide pressure (pCO₂), partial oxygen pressure (pO₂), bicarbonate (HCO₃⁻), and oxygen saturation percentage (sO₂%). Due to expected individual variability among animals, pre- and post-treatment values were statistically compared within each group using the paired samples t-test, and results were considered significant at $P < 0.05$.

CD3⁺, CD4⁺, and CD8⁺ cell percentages were determined by flow cytometry. EDTA blood samples taken from rats were stained with Anti-Rat CD3⁺, CD4⁺, and CD8⁺ monoclonal antibodies (Elabscience, manufacturer country not specified), and CD3⁺, CD4⁺, and CD8⁺ cell

percentages were determined using the Beckman Coulter CytoFLEX flow cytometry device.

Serum IL-1, IL-33, HMGB1, and lung homogenate MMP-9 and TIMP-1 levels were measured using ELISA kits (BT LAB, China). Samples and standards were prepared as specified in the kit. After incubation and washing, the reactions were stopped, and absorbance values were recorded.

The researchers performing the histopathological, biochemical, and immunological evaluations were blinded to the group allocations to minimize assessment bias.

Statistical analysis

All analyses were performed using SPSS version 29. The Shapiro-Wilk test was used to assess normality, and the Levene test was used to assess homogeneity of variance. Parametric data were analyzed using ANOVA and Tukey's HSD post hoc test, while non-parametric data were evaluated using the Kruskal-Wallis H test. A P -value < 0.05 was considered statistically significant. R Statistical Language version 4.5.0 (www.r-project.org) was used to visualize blood gas results.

Results

Chemical and phenolic composition of *O. onites* L. and *O. minutiflorum*

As a result of the analysis of the essential oil of *O. onites* L., the highest amount of carvacrol (66.75%) was detected. Thymoquinone was second with 29.46%. As a result of the analysis of the essential oil of *O. minutiflorum*, the highest amount of carvacrol (77.56%) was detected, followed by thymoquinone with 11.32%. Thymol was detected at 7.69%. The components found in the essential oil of *O. onites* L. and *O. minutiflorum* are shown in Table 2.

As a result of the phenolic substance analysis of *O. onites* L., the highest levels of rosmarinic acid (2295.4 ppm), hesperidin (180.3 ppm), luteolin (174.8 ppm), and catechin (95.5 ppm) were detected. As a result of the phenolic substance analysis of *O. minutiflorum*, the highest levels of rosmarinic acid (885.8 ppm) and kaempferol (148.6 ppm) were detected. In addition, as shown in Table 3, substances with known antioxidant activity, such as gallic acid, epicatechin, and benzoic acid, were detected in both origanum species.

Free radical scavenging activity of the honey

According to Table 4; radical scavenging activity was determined as 40.98% in the honey sample at a

Table 1. Semi-quantitative scoring system for histopathological findings rat lung tissues

Score	Emphysema	Inflammation	Lymphoid aggregation	Fibrosis, necrosis, granuloma
0	None: Normal alveolar structure	None: No signs of inflammation	None: No lymphoid accumulation	None: No pathological findings
1	Mild: Minimal alveolar enlargement	Mild: Slight inflammatory cell infiltration	Mild: Small and irregular clusters	Mild: Limited and focal pathological changes
2	Moderate: Noticeable alveolar destruction	Moderate: Moderate infiltration and disruption	Moderate: Localized lymphoid aggregations	Moderate: More extensive but confined changes
3	Severe: Widespread alveolar destruction	Severe: Diffuse infiltration and tissue damage	Severe: Dense and organized lymphoid nodules	Severe: Extensive or structurally disruptive changes

Table 2. Chemical composition of the essential oils of *Origanum onites* L. and *Origanum minutiflorum*

Chemical Component	<i>Origanum onites</i> Area (%)	<i>Origanum minutiflorum</i> Area (%)
Benzeneacetaldehyde	0.09	
4-Terpineol	0.08	0.70
Thymoquinone	29.46	11.32
2-Acetyl-4,4-dimethyl-cyclopent-2-enone	0.49	
Thymol	0.83	7.69
Carvacrol	66.75	77.56
2,4-Di-tert-butylphenol	0.13	0.13
Heptadecane	0.25	0.20
Nonadecane	1.80	1.20
Pentacosane	0.13	0.07
Octen-3-ol		0.53
Octan-3-ol		0.18
Simol 47804		0.05
1,2,3-Trimethyl-cyclopent-2-enecarboxaldehyde		0.03
Borneol		0.04
Dihydrocarvone		0.27
Heptadecanol		0.03

Table 3. Phenolic compound content of *Origanum onites* L. and *Origanum minutiflorum* (ppm)

Phenolic Compound	<i>Origanum minutiflorum</i> (ppm)	<i>Origanum onites</i> L. (ppm)
Gallic acid	26.2	16.9
Protocatechuic acid	10.9	7.6
Catechin	36.3	95.5
<i>p</i> -Hydroxybenzoic acid	3.1	–
Chlorogenic acid	2.9	14.3
Caffeic acid	41.8	52.8
Epicatechin	6.3	22.7
Ferulic acid	10.1	36.5
Benzoic acid	28.9	8.5
Hesperidin	115.0	185.3
Rosmarinic acid	885.8	2295.4
Cinnamic acid	2.6	–
Quercetin	–	50.4
Luteolin	20.3	174.8
Kaempferol	148.6	56.5

Table 4. Radical scavenging activity (%RSA) of honey samples at different

Concentration (mg/ml)	% Radical Scavenging Activity (Mean ± SD)	IC ₅₀ (=SC ₅₀) (mg/ml)
5	40.98 ± 0.38	
10	47.90 ± 0.06	15.301
20	52.00 ± 0.09	
40	59.55 ± 0.16	

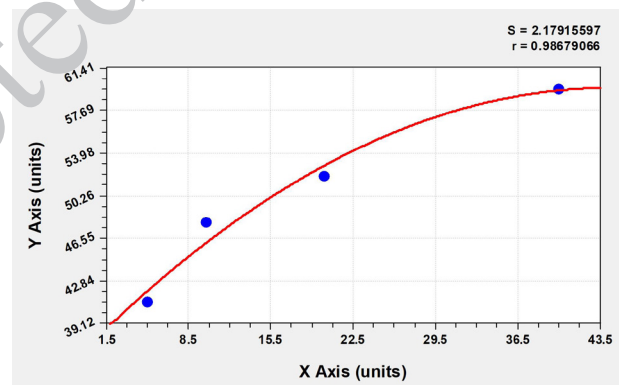
concentration of 5 mg/ml, 47.90% in the honey sample at a concentration of 10 mg/ml, 52% in the honey sample at a concentration of 20 mg/ml, and 59.55% in the honey sample at a concentration of 40 mg/mL. According to the results, the IC₅₀ (SC₅₀) value was 15.301, as determined from the graph in Figure 2.

Flow cytometry analyses (CD3⁺, CD4⁺, CD8⁺)

CD3⁺ T cell percentages differed significantly among groups ($P=0.017$), with the highest expression in the *O. minutiflorum* group and the lowest in the COPD group. CD8⁺ levels also showed significant group differences ($P=0.03$), while CD4⁺ levels did not differ significantly ($P=0.33$) (Table 5).

Blood gas parameters

Blood gas parameters were evaluated before and after the experimental period in each group. Notably, although

**Figure 2.** Dose-response curve of the radical scavenging activity of honey (DPPH assay)**Table 5.** Distribution of CD3⁺ and CD8⁺ T cell percentages among experimental groups of rats

	Control (n=6)	COPD (n=7)	<i>Origanum onites</i> (n=8)	<i>Origanum minutiflorum</i> (n=7)	Honey (n=7)	P-value
	Median IQR [Q1-Q3]	Median IQR [Q1-Q3]	Median IQR [Q1-Q3]	Median IQR [Q1-Q3]	Median IQR [Q1-Q3]	
CD3 ⁺ (%)	50.86 [0 65.86] ^a	74.87 [66.06 83.42] ^b	59.36 [49.83 61.07] ^a	57.87 [41.88 62.38] ^a	60.52 [52.03 68.23] ^a	0.017*
CD4 ⁺ (%)	31.28 [0 46.82]	42.12 [38.91 51.45]	41.18 [35.82 43.96]	40.68 [28.79 43.31]	40.37 [35.91 46.35]	0.334
CD8 ⁺ (%)	17.11 [0 18.61] ^a	21.69 [19.34 42.52] ^b	14.83 [13.24 15.71] ^a	13.83 [10.53 18.95] ^a	17.38 [15.09 22.19] ^a	0.033*

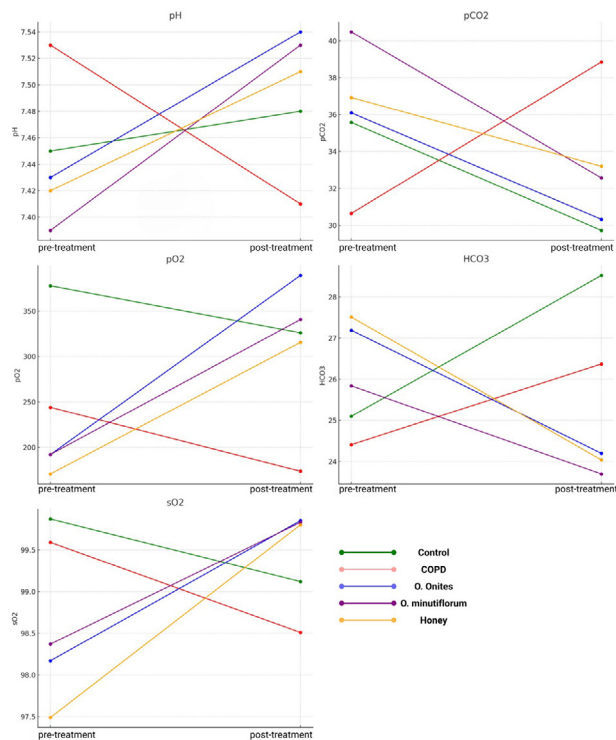


Figure 3. Line graphs showing group means of pH, pCO₂, pO₂, HCO₃⁻, and sO₂ values measured at baseline (3 days after COPD induction) and after the 15-day treatment period

COPD was induced using the same protocol across all groups, baseline (pre-treatment) values of pCO₂ and pO₂ varied slightly between groups, possibly due to individual physiological differences. In the COPD group, disease induction led to a significant decrease in pH (7.53 ± 0.04 to 7.41 ± 0.05 , $P=0.005$) and an increase in pCO₂ (30.64 ± 0.25 to 38.86 ± 5.27 mmHg, $P=0.018$). Treatments with *O. onites* L., *O. minutiflorum*, and honey significantly improved pH levels (7.43 ± 0.04 to 7.54 ± 0.08 , $P=0.015$; 7.39 ± 0.03 to 7.53 ± 0.07 , $P=0.012$; 7.42 ± 0.05 to 7.51 ± 0.05 , $P=0.007$, respectively). pCO₂ levels significantly decreased in the *O. onites* L. (36.1 ± 4.48 to 30.32 ± 7.9 mmHg, $P=0.048$) and *O. minutiflorum* (40.49 ± 5.39 to 32.57 ± 4.32 mmHg, $P=0.001$)

groups. pO₂ levels significantly increased after treatment in the *O. onites* L. (192.12 ± 90.86 to 389 ± 76.95 mmHg, $P=0.012$) and honey (170.86 ± 53.32 to 315.43 ± 56.29 mmHg, $P=0.013$) groups. sO₂ levels were significantly elevated only in the honey group (97.49 ± 1.79 to 99.8 ± 0.13 , $P=0.024$) (Figure 3). All statistical comparisons were performed using a paired samples t-test ($P < 0.05$ considered significant). It is important to note that all animals were exposed to identical procedures; however, minor baseline variations in blood gas parameters were observed, possibly due to individual physiological differences. Therefore, pre- and post-treatment comparisons were statistically evaluated within each group, rather than between groups, to assess treatment effects accurately.

Cytokines and protein markers

The amount of IL-1α was significantly elevated in the COPD group ($46,94 \pm 5,01$ ng/l), while treatment with *O. minutiflorum* resulted in the lowest IL-1α amount ($33,86 \pm 4,35$ ng/l) ($P < 0.001$). IL-33 amounts were also highest in the COPD group ($142,81 \pm 18,71$ ng/l), and significantly lower in the *O. minutiflorum* ($96,96 \pm 28,38$ ng/l) and honey groups ($100,42 \pm 28,57$ ng/l) ($P=0.004$).

The highest HMGB1 amount was observed in the COPD group ($6,05 \pm 0,45$ ng/ml), while all treatment groups showed a reduction, especially *O. minutiflorum* ($4,36 \pm 0,69$ ng/ml) ($P=0.003$). MMP-9 amounts increased in the COPD group ($2,4 \pm 0,28$ ng/ml) and significantly decreased in the treatment groups, with the lowest amount again in *O. minutiflorum* ($1,50 \pm 0,23$ ng/ml) ($P < 0.001$).

TIMP-1 amounts were significantly higher in the honey group ($1,93 \pm 0,25$ ng/ml) and lowest in the COPD group ($1,41 \pm 0,14$ ng/ml), with moderate increases observed in the other treatment groups ($P=0.021$) (Table 6). These findings suggest that *O. minutiflorum* notably reduced inflammatory and tissue-damage markers, while honey appeared to enhance anti-proteolytic response.

Pearson correlation analysis was performed to evaluate the relationships between HMGB1, IL-1α, IL-33, MMP-9, and TIMP-1 levels in all groups. The results revealed a positive correlation between HMGB1 and MMP-9, as well as between IL-1α and both IL-33 and MMP-9.

Table 6. Distribution of serum HMGB1, IL-1α, IL-33, MMP-9 and TIMP-1 levels among experimental groups of rats

	Control (n=6)	COPD (n=7)	<i>Origanum onites</i> (n=8)	<i>Origanum minutiflorum</i> (n=7)	Honey (n=7)	P-value
	Mean±SD	Mean±SD	Mean±SD	Mean±SD	Mean±SD	
HMGB1 (ng/ml)	4,52±0,75 ^a	6,05±0,45 ^b	4,49±0,84 ^a	4,36±0,69 ^a	4,68±0,9 ^a	0,003*
IL-1α (ng/l)	42,9±5,66 ^{ab}	46,94±5,01 ^a	37,62±2,95 ^{bc}	33,86±4,35 ^c	38,41±4,32 ^{bc}	<0,001*
IL-33 (ng/l)	130,99±20,56 ^{ab}	142,81±18,71 ^b	113,68±8,58 ^{ab}	96,96±28,38 ^a	100,42±28,57 ^a	0,004*
MMP-9 (ng/ml)	1,52±0,3 ^a	2,4±0,28 ^b	1,58±0,3 ^a	1,50±0,23 ^a	1,61±0,2 ^a	<0,001*
TIMP-1 (ng/ml)	1,49±0,33 ^{ab}	1,41±0,14 ^a	1,64±0,29 ^{ab}	1,59±0,22 ^{ab}	1,93±0,25 ^b	0,021*

¹One-way ANOVA

² $P < 0.05$ was considered statistically significant

³Values sharing the same letter are not significantly different

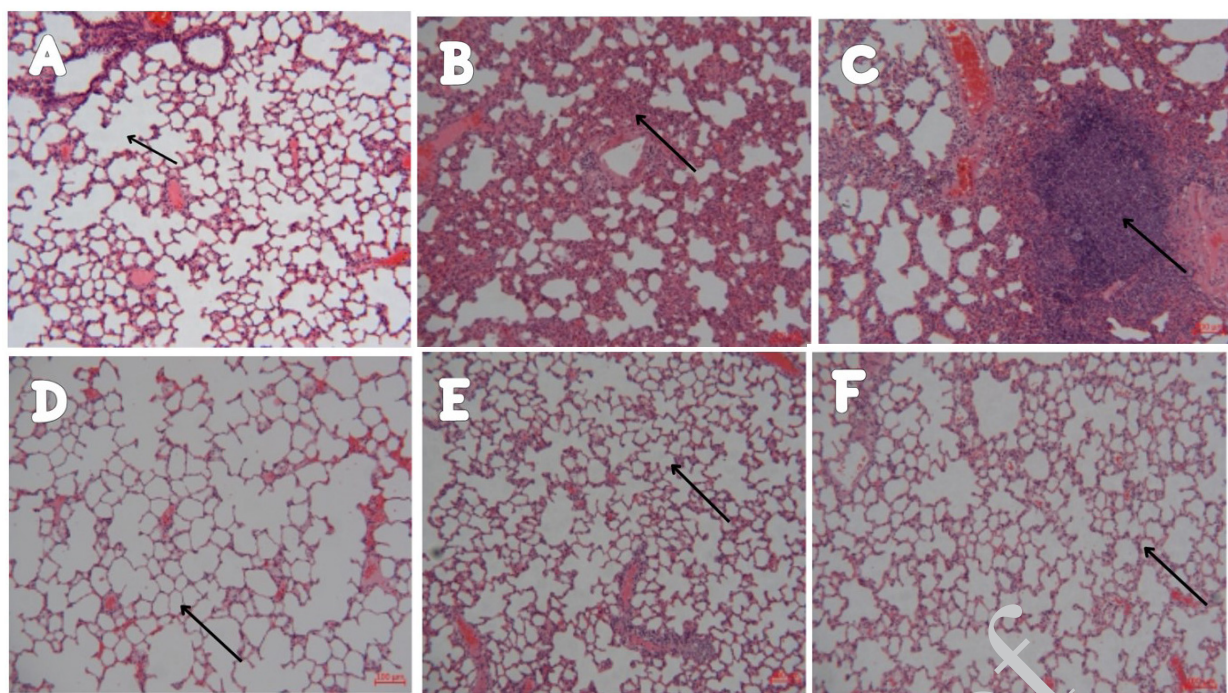


Figure 4. Histopathological images of lung tissues stained with hematoxylin and eosin (H&E) from the sham group and treatment groups following PPE-induced COPD in rats. In the sham group, representative images show emphysematous changes (A), inflammatory cell infiltration (B), and lymphoid accumulation (C) under light microscopy at 100× magnification. Panels (D), (E), and (F) represent lung tissue sections from rats treated with *Origanum onites* L., *Origanum minutiflorum*, and honey, respectively, all visualized at 100× magnification

Histopathological findings

Histopathological analysis demonstrated (Figure 4):

- The honey group exhibited the lowest emphysema score, whereas the COPD group had the highest ($P < 0.05$) (Table 7).
- Inflammation scores were decreased in all treatment groups, although the change was not statistically significant ($P > 0.05$) (Table 7).
- Lymphoid aggregates were observed only in the COPD group (Table 7).
- No fibrosis or granuloma formations were detected in any group.

Discussion

In the PPE-induced COPD model, characteristic

alterations such as hypoxemia, hypercapnia, and acidosis are typically observed due to impaired gas exchange and ventilatory dysfunction. Consistent with these features, our study demonstrated significantly reduced pO_2 and pH levels, and increased pCO_2 in the COPD group ($P = 0.005$) (26). These findings mirror previous reports indicating that elastase exposure leads to hypoventilation and respiratory acidosis.

Therapeutic interventions such as dexmedetomidine (27), low molecular weight Heparin (28), baicalin (29), gallic acid (30), and heliox therapy (31) have been shown to reverse these changes. In alignment, our study found significant increases in pO_2 in the *O. onites* ($P = 0.012$) and honey ($P = 0.013$) treated groups, along with significant

Table 7. Histopathological evaluation scores of inflammation, lymphoid aggregation, and emphysema in the experimental groups of rats

	Inflammation	Emphysema	Lymphoid aggregation
	Mean (%95 CI)	Mean (%95 CI)	Mean (%95 CI)
Control (n=6)	1,29 (0,83-1,73)	0,71 (0,26-1,17) ^{ab}	0 (0-0) ^a
COPD (n=7)	1,57 (1,08-2,07)	0,86 (0,22-1,5) ^a	1,57 (0,17-2,97) ^b
<i>Origanum onites</i> (n=8)	1,12 (0,43-1,82)	0,5 (0,05-0,95) ^{ab}	0 (0-0) ^a
<i>Origanum Minutiflorum</i> (n=7)	1,14 (0,5-1,78)	0,29 (0-0,73) ^{ab}	0 (0-0) ^a
Honey (n=7)	1 (0,24-1,76)	0 (0-0) ^b	0 (0-0) ^a
P-value	0,597	0,024*	0,000*

* One-way ANOVA

¹ Values are presented as mean (95% confidence interval, lower–upper limits)

² Values sharing the same letter are not significantly different

³ $P < 0.05$ was considered statistically significant

decreases in $p\text{CO}_2$ in the *O. onites* ($P=0.048$) and *O. minutiflorum* ($P=0.001$) groups. Although $p\text{CO}_2$ reduction in the honey group did not reach statistical significance ($P=0.314$), all treatment groups demonstrated a significant pH increase ($P<0.05$), indicating partial correction of acidosis. Moreover, sO_2 improvement in the honey group ($P=0.024$) is consistent with prior evidence of enhanced oxygenation following antioxidant interventions.

T cell analysis revealed significantly elevated CD3^+ and CD8^+ T cell levels in the COPD group, indicating heightened immune activation. CD8^+ T cells have been extensively implicated in COPD pathogenesis, contributing to cytotoxic damage and tissue remodeling (32,33). Treatment with *O. onites*, *O. minutiflorum*, and honey significantly reduced CD8^+ T cell levels, while CD4^+ levels remained unchanged, highlighting the specific immunomodulatory effects targeting cytotoxic lymphocyte populations.

HMGB1, IL-1 α , and IL-33 are damage-associated molecular pattern (DAMP) molecules and alarmin cytokines that initiate and sustain pulmonary inflammation. Elevated HMGB1 levels, often associated with IL-1 β and epithelial injury, have been reported in COPD patient sputum and serum (34,35). Our findings showed that HMGB1 was significantly elevated in the COPD group but markedly reduced in all treatment groups, suggesting that honey and Origanum extracts effectively suppress inflammation at a molecular level.

Similarly, IL-1 α and IL-33, both epithelial-derived alarmins, were significantly elevated in the COPD group and most strongly suppressed in the *O. minutiflorum* and honey-treated groups. These results suggest that these treatments interfere with the upstream signaling events that drive chronic airway inflammation, potentially via NF- κB and TLR4 inhibition and Nrf2 pathway activation. Phytochemicals such as carvacrol, thymol, and thymoquinone, abundantly present in Origanum species, likely contribute to these anti-inflammatory effects.

MMP-9, a protease responsible for extracellular matrix degradation, was significantly elevated in the COPD group, consistent with prior studies (36, 37). All treatment groups exhibited a significant reduction in MMP-9 levels, with *O. minutiflorum* producing the most pronounced decrease. TIMP-1, an endogenous inhibitor of MMPs, was lowest in the COPD group but significantly increased only in the honey group, indicating honey's unique potential to restore protease-antiprotease balance. This restoration is critical in preventing alveolar destruction and tissue remodeling, hallmarks of advanced COPD.

Histopathological analysis further supported these findings. The COPD group exhibited the most severe emphysema, alveolar wall destruction, and inflammatory cell infiltration. In contrast, the honey-treated group showed the most marked histological improvement, with significantly lower emphysema scores and minimal inflammation. Notably, lymphoid aggregates were detected only in the COPD group, suggesting that treatment mitigated chronic immune activation. Absence of fibrosis or granulomas across all groups may reflect the relatively short experimental duration or limitations of the elastase model in mimicking late-stage COPD.

The phytochemical profiles of *O. onites* and *O. minutiflorum* provide a plausible explanation for the observed therapeutic effects. Both species are rich in

carvacrol, though levels were higher in *O. minutiflorum*. *O. onites* also contains high levels of rosmarinic acid, hesperidin, and luteolin—compounds known for anti-inflammatory and antioxidant activities. Organic acids such as malic and citric acid found in these plants may also contribute to mucus modulation and metabolic support. Honey, on the other hand, contains flavonoids and phenolic acids with established roles in immune modulation and tissue repair (38, 39).

Taken together, our findings demonstrate that *O. onites*, *O. minutiflorum*, and honey possess significant therapeutic potential in the management of COPD. These agents reduced inflammatory cytokine levels, restored T cell balance, improved gas exchange, and mitigated tissue damage. The effects are likely mediated by multifaceted mechanisms, including inhibition of pro-inflammatory pathways (NF- κB , TLR4), activation of antioxidant responses (Nrf2), and modulation of protease activity (MMP-9/TIMP-1). These results support the potential use of Origanum species and honey as complementary therapeutic strategies in COPD management, warranting further clinical investigation to assess their long-term efficacy and safety.

Conclusion

In this study, the therapeutic effects of *O. onites* L., *O. minutiflorum*, and honey were investigated in an elastase-induced COPD model. The findings suggest that these natural products may exert protective effects against COPD pathophysiology by suppressing inflammation, modulating immune balance, and restoring the protease-antiprotease equilibrium. Notably, *O. minutiflorum* was particularly effective in reducing IL-1 α and MMP-9 levels, while honey stood out by increasing TIMP-1 levels and lowering emphysema scores. These results indicate that thyme species and honey may hold potential as complementary or supportive agents in COPD treatment. Further experimental and clinical studies are needed to validate these findings and advance their therapeutic application.

Acknowledgment

The results described in this paper were part of a student's thesis.

Ethical Approval

Ethical approval was granted by the Selçuk University Experimental Medicine Application and Research Center Animal Experiments Local Ethics Committee with decision number 2023-26.

Availability of Data and Materials

The datasets generated and/or analyzed during the current study are available from the corresponding author upon reasonable request.

Authors' Contributions

F O contributed to conceptualization, methodology, investigation, data curation, formal analysis, visualization, writing the original draft, review and editing, and project administration. Hu V contributed to supervision, validation, resources, and review and editing of the manuscript. Ha V was responsible for investigation, data curation, software, and formal analysis. B C contributed to methodology, project administration, and resources. ih handled histopathological

analysis, visualization, and validation.

Conflicts of Interest

The authors declare that they have no conflicts of interest.

Declaration

Artificial intelligence (ChatGPT, OpenAI) was used solely for language editing purposes. All scientific content was written and verified by the authors.

References

- Sandelowsky H, Weinreich UM, Aarli BB, Sundh J, Høines K, Stratelis G, et al. COPD – do the right thing. BMC Fam Pract 2021; 22: 244–271.
- Ballarin A, Bazzan E, Zenteno RH, Turato G, Baraldo S, Zanovello D, et al. Mast cell infiltration discriminates between histopathological phenotypes of chronic obstructive pulmonary disease. Am J Respir Crit Care Med 2012; 186: 233–239.
- Barnes PJ. Inflammatory mechanisms in patients with chronic obstructive pulmonary disease. J Allergy Clin Immunol 2016; 138: 16–27.
- Martinez-Garcia MA, Miravittles M. Bronchiectasis in COPD patients: More than a comorbidity? Int J Chron Obstruct Pulmon Dis 2017; 12: 1401–1411.
- GOLD. Global strategy for the diagnosis, management, and prevention of chronic obstructive pulmonary disease: 2021 report. Global Initiative for Chronic Obstructive Lung Disease; 2021.
- Chen HY, Ma CH, Cao KJ, Chung-Man Ho J, Ziea E, Wong VT, et al. A systematic review and meta-analysis of herbal medicine on chronic obstructive pulmonary diseases. Evid Based Complement Alternat Med 2014; 2014: 925069–925080.
- Canli K, Bozyel ME, Turu D, Benek A, Simsek O, Altuner EM. Biochemical, antioxidant properties and antimicrobial activity of steno-endemic *Origanum onites*. Microorganisms 2023; 11: 1087–2001.
- Vanti G, Tomou EM, Stojković D, Ćirić A, Bilia AR, Škalčić L. Nanovesicles loaded with *Origanum onites* and *Satureja thymra* essential oils and their activity against food-borne pathogens and spoilage microorganisms. Molecules 2021; 26: 2124–2139.
- Can Baser K. Biological and pharmacological activities of carvacrol and carvacrol bearing essential oils. Curr Pharm Des 2008; 14: 3106–3119.
- Peng X, Zhang X, Sharma G, Dai C. Thymol as a potential neuroprotective agent: Mechanisms, efficacy, and future prospects. J Agric Food Chem 2024; 72: 6807–6814.
- Peter S, Sotondoshe N, Aderibigbe BA. Carvacrol and thymol hybrids: potential anticancer and antibacterial therapeutics. Molecules 2024; 29: 2277–2295.
- Tepe B, Cakir A, Sihoglu Tepe A. Medicinal uses, phytochemistry, and pharmacology of *Origanum onites* (L.): A review. Chem Biodiver 2016; 13: 504–520.
- Tungmunthithum D, Thongboonyou A, Pholboon A, Yangsabai A. Flavonoids and other phenolic compounds from medicinal plants for pharmaceutical and medical aspects: An overview. Medicines 2018; 5: 93–109.
- Sari I, Donmez Arat G, Ozkan O, Aydemir I, Ozbey C, Tuğlu MI. Apoptotic and cytotoxic effect of *Origanum minutiflorum* on NB2A neuroblastoma cells. Ankara Univ Eczac Fak Derg 2020; 44: 281–292.
- Veljovic K, Tesevic V, Mitrovic H, Stankovic M. Essential oil of *Origanum minutiflorum* exhibits anti-inflammatory and antioxidative effects in human bronchial cells and antimicrobial activity on lung pathogens. J Herb Med 2023; 39: 100651.
- Altundag S, Aslim B, Ozturk S. *In vitro* antimicrobial activities of essential oils from *Origanum minutiflorum* and *Sideritis erythrantha* subsp. *Erythrantha* on phytopathogenic bacteria. J Essential Oil Res 2011; 23: 4–8.
- Vardar-Ünlü G, Ünlü M, Dönmez E, Vural N. Chemical composition and *in vitro* antimicrobial activity of the essential oil of *Origanum minutiflorum* O Schwarz & PH Davis. J Sci Food Agric 2007; 87: 255–259.
- Erejuwa OO, Nwobodo NN, Akpan JL, Okorie UA, Ezeonu CT, Ezeokpo BC, et al. Nigerian honey ameliorates hyperglycemia and dyslipidemia in alloxan-induced diabetic rats. Nutrients 2016; 8: 95–109.
- Ajibola A, Chamunorwa JP, Erlwanger KH. Nutraceutical values of natural honey and its contribution to human health and wealth. Nutr Metab 2012; 9: 61–73.
- Borzzone G, Liberona L, Olmos P, Sáez C, Meneses M, Reyes T, et al. Rat and hamster species differences in susceptibility to elastase-induced pulmonary emphysema relate to differences in elastase inhibitory capacity. Am J Physiol Regul Integr Comp Physiol 2007; 293: 1342–1349.
- Ghaderi A, Asaad Karimi S, Talaei F, Shahidi S, Faraji N, Komaki A. The effects of aqueous extract of *Origanum vulgare* on learning and memory in male rats Implication for health policy/practice/research/medical education. J Herbmed Pharmacol 2020; 9: 239–244.
- Habibi E, Shokrzadeh M, Chahra A, Naghshvar F, Keshavarz-Maleki R, Ahmadi A. Protective effects of *Origanum vulgare* ethanol extract against cyclophosphamide-induced liver toxicity in mice. Pharm Biol 2015; 53: 10–15.
- Sharifi-Rigi A, Heidarian E, Zal F. Protective effects of hydroalcoholic leaf extract of *Origanum vulgare* against paraquat-induced lung toxicity in rats: The role of the inflammation-related markers and oxidative stress. Nat Prod J 2023; 14: 1–9.
- Nasri M, Zaouani M, Mimoun N, Hani FA, Mahdid M, Toumi M. Antidiyabetik etkinliğin değerlendirilmesi Alloxan kaynaklı diyabetik sıçanlarda Wistar'da *Origanum Floribundum* Munby yapraklarının Sulu Ekstresinin Y'si. J Biol Res 202; 93: 102–106.
- Hemmati M, Karamian M, Malekaneh M. Anti-atherogenic potential of natural honey: Anti-diabetic and antioxidant. J Pharm Pharmacol 2015; 3: 278–284.
- Shiraishi M, Yoshida M, Aritomi T, Murakami H, Toyoshima H, Senju S. Levels of α-elastin and of desmosine as indexes of elastase-induced lung injury in rats. Jpn J Thorac Dis 1996; 34: 404–412.
- Li P, Han J, Zhang D, Cao S, Su C. Effects of dexmedetomidine on oxidative stress and inflammatory response in lungs during mechanical ventilation in COPD rats. Exp Ther Med 2020; 19: 1219–1224.
- Wang YQ, Sun NN, Cheng ZZ, Tong L. Optimal time to use low molecular weight heparin on prethrombotic state of rat chronic obstructive pulmonary disease model. Chin Med J (Engl) 2014; 127: 518–521.
- Wang G, Mohammadursun N, Lv Y, Zhang H, Sun J, Dong J. Baicalin exerts anti-airway inflammation and anti-remodelling effects in severe stage rat model of chronic obstructive pulmonary disease. Evid Based Complement Alternat Med 2018; 2018: 7591348–759162.
- Sohrabi F, Dianat M, Badavi M, Radan M, Mard SA. Gallic acid suppresses inflammation and oxidative stress through modulating Nrf2-HO-1-NF-κB signaling pathways in elastase-induced emphysema in rats. Environ Sci Pollut Res 2021; 28: 56822–56834.
- Wu W, Chen X, Liu X, Liu C, Lu G. Heliox-driven nebulization has a positive effect on the lung function in lipopolysaccharide-induced chronic obstructive pulmonary disease rat model. Med Sci Monit 2016; 22: 4100–4106.
- Hodge G, Mukaro V, Reynolds PN, Hodge S. Role of increased CD8/CD28 null T cells and alternative co-stimulatory molecules in chronic obstructive pulmonary disease. Clin Exp Immunol 2011; 166: 94–102.
- Yang Y, Feng Y, Liang A, Pan L, Liang W, Yang H. Effects of Ginkgo biloba Extract on T cell subsets in rats with chronic obstructive pulmonary disease. Chin J Integr Tradit West Med 2018; 38: 851–854.
- Ferhani N, Letuve S, Kozhich A, Thibaudeau O, Grandsaigne M, Maret M, et al. Expression of high-mobility group box 1 and of receptor for advanced glycation end products in chronic obstructive pulmonary disease. Am J Respir Crit Care Med 2010;

181: 917-927.

35. Xu W, Wu J, Feng Y, Zhu J, Cui R. Clinical significance of serum HMGB1 in COPD and correlation with severity of airflow restriction and immune function. *Rev Rom Med Lab* 2022; 30: 173-181.

36. Li H, Cui D, Tong X, Ma N, Gao Y, Cui X, *et al.* The role of matrix metalloproteinases in extracellular matrix remodelling in chronic obstructive pulmonary disease rat models. *Zhonghua Nei Ke Za Zhi* 2002; 41: 393-398.

37. Sun J, Bao J, Shi Y, Zhang B, Yuan L, Li J, *et al.* Effect of

simvastatin on MMPs and TIMPs in cigarette smoke-induced rat COPD model. *Int J Chron Obstruct Pulmon Dis* 2017; 11: 717-724.

38. Muhamad R, Draman N, Aziz AA, Abdullah S, Jaeb MZM. The effect of Tualang honey on the quality of life of patients with chronic obstructive pulmonary disease: A randomized controlled trial. *J Taibah Univ Med Sci* 2018; 13: 42-50.

39. Zare z, Balouchi A, Shahdadi H, Bandadni E. The effect of honey on relieving coughs in elderly patients diagnosed with chronic obstructive pulmonary disease: A clinical trial. *Int J Pharm Clin Res* 2016; 8: 1218-1221.

Corrected Proof