

## Dietary saffron reduced the blood pressure and prevented remodeling of the aorta in L-NAME-induced hypertensive rats

Zohreh Nasiri <sup>1</sup>, Hamid Reza Sameni <sup>2</sup>, Abedin Vakili <sup>1</sup>, Morteza Jarrahi <sup>1</sup>, Mahdi Zahedi Khorasani <sup>1\*</sup>

<sup>1</sup> Research Center and Department of Physiology, Faculty of Medicine, Semnan University of Medical Sciences, Semnan, Iran

<sup>2</sup> Neural Stem Cells Research Center and Department of Anatomical Sciences, Faculty of Medicine, Semnan University of Medical Sciences, Semnan, Iran

### ARTICLE INFO

#### Article type:

Short communication

#### Article history:

Received: Feb 2, 2015

Accepted: Jun 18, 2015

#### Keywords:

Aorta

Histology

Hypertension

L-NAME

Saffron

### ABSTRACT

**Objective(s):** The aim of this study was to investigate the effects of nutritional saffron (*Crocus sativus* L.) stigma hydroalcoholic extract on blood pressure (BP) and histology of the aorta in normotensive and hypertensive rats.

**Materials and Methods:** Saffron (200 mg/kg/day) was given orally for 5 weeks to normotensive and hypertensive rats. Hypertension was induced by NG-nitro-L-arginine methyl ester (L-NAME; 40 mg/kg/day) administration in drinking water, and BP was measured weekly. Histological examination of the thoracic aorta included staining with hematoxylin and eosin, orcein, and periodic acid Schiff methods.

**Results:** Saffron had no effect on normotensive rats, but on hypertensive rats, prevented BP elevation from the third week of treatment ( $P < 0.001$ ). Furthermore, saffron reduced the cross-section area, media thickness, and elastic lamellae number of the aorta ( $P < 0.05$ ).

**Conclusion:** Nutritional saffron prevented BP increases and remodeling of the aorta in hypertensive rats. It may be useful for preventing hypertension.

#### ► Please cite this article as:

Nasiri Z, Sameni HR, Vakili A, Jarrahi M, Zahedi Khorasani M. Dietary saffron reduced the blood pressure and prevented remodeling of the aorta in L-NAME-induced hypertensive rats. Iran J Basic Med Sci 2015; 18:1143-1146.

### Introduction

*Crocus sativus* L., commonly known as saffron, is a fragrant plant that belongs to the Iridaceae family. It is cultivated in several countries including Iran. Saffron has been used in traditional medicine for several purposes (1), as it has many pharmacological effects including antioxidant (2), analgesic, anti-inflammatory, anticonvulsant, anti-anxiety, aphrodisiac, antidepressant, (1) and bronchodilator activity (3). In addition, saffron and its constituents have cardiovascular properties that include hypotensive (4) and cardioprotective effects in rats (5), platelet aggregation inhibition and membrane lipid peroxidation in humans (6), and antiatherosclerosis effects in rabbits (7). Furthermore, it has been reported that chronic IP administration of saffron stigma aqueous extract and its major components: crocin and safranal reduced systolic blood pressure (BP) of desoxycorticosterone acetate (DOCA)-salt induced hypertensive rats (8-10).

Nitric oxide (NO) which plays an important role in maintaining normal BP and essential hypertension is associated with defects in the NO. Chronic administration of NO synthase (NOS) inhibitor, NG-

nitro-L-arginine methyl ester (L-NAME), caused a significant increase in BP of experimental animal, a particularly interesting model of hypertension which looks like essential hypertension model (11) that was used in this study.

Saffron is used extensively as a food additive in Iran and other countries, but its dietary effects on BP and aorta remodeling in hypertensive rat are not well known. So, the aim of this study was to investigate the nutritional effects of saffron stigma hydroalcoholic extract on BP and histological changes of the thoracic aorta in normotensive and L-NAME induced hypertensive rats.

### Materials and Methods

#### Animals and drugs

The experimental protocol was approved by the Ethical Review Board of Semnan University of Medical Sciences, Iran (license number: 91.7861). All experimental trials were conducted in agreement with the National Institutes of Health Guide for Care and Use of Laboratory Animals. Male Wistar rats were obtained from the breeding colony of Semnan University of Medical Sciences, Semnan,

\*Corresponding author: Mahdi Zahedi Khorasani. Research Center and Department of Physiology, Faculty of Medicine, Semnan University of Medical Sciences, Semnan, Iran. 5<sup>th</sup> Km of Damquan road. Tel: +98-23333654218; email: zahedikhorasani@yahoo.com

Iran. Animals were housed in individual cages in a 12-hr light/dark cycle at 22–24 °C, with food and water available *ad libitum*.

The drugs used in this study including thiopental sodium and L-NAME, were obtained from Sigma-Aldrich; heparin was obtained from TRITTAU, Germany. Drugs and extracts were dissolved in saline.

### Experimental procedure

#### Nutritional effects of Saffron on BP

To determine chronic effects (dietary) of saffron on BP and the histomorphometry of the aorta in hypertensive and normotensive rats, 28 male Wistar rats (180–220 g) were divided randomly and equally into the following four experimental groups: (1) L-NAME plus vehicle, (2) L-NAME plus saffron, (3) vehicle plus vehicle, and (4) vehicle plus saffron. Hypertension was induced by L-NAME (40 mg/kg/day) administration through drinking water for 5 weeks (11); saffron (200 mg/kg/day) or its vehicle was given orally during this period. BP was measured noninvasively weekly with the cuff method (Power lab-Australia) and invasively at the final step of experiment.

#### Histomorphometry

Rats in the chronic groups and normal group were sacrificed under deep anesthesia at the end of the experiment. The thoracic aorta segments were removed and fixed in 10% formalin solution for 48 hr. The samples were embedded in paraffin and handled with routine tissue processing. The 5 µm sections were stained by hematoxylin and eosin (H&E), orcein, and periodic acid Schiff (PAS) methods. Magnified digital images of the stained aortic slices were obtained with a digital camera (Nikon, CoolPix S10, Japan) attached to a light microscope (Zeiss, Germany). All slides were evaluated using a light microscope, which was calibrated by an ocular micrometer. The aortic cross-sectional area, aortic wall thickness, tunica media thickness (from the internal to the external elastic lamellae), and number and thickness of elastic lamellae were calculated in ten areas of five random sections of the thoracic aorta obtained from each animal.

#### Plant and extract preparation

Saffron stigma (*Crocus sativus L.*) was prepared from Ghaen city in Khorasan Province, Iran, in the fall of 2012 and certified by botanists in the Organization of Promotion, Education, and Agricultural Research-Semnan. Saffron stigma was ground, and 10 g of its powder was added to 1000 ml of 70% ethanol. The mixture was warmed to 50 °C while mixing on a hotplate stirrer (Sana-Iran) for about 30 min. The solution was filtered, dried by oven at 40 °C, and stored in refrigerator. The yield of the extract was about 30%. The dried extract was dissolved in saline daily to make different doses of saffron.

### Statistical analysis

The results are presented as the mean±SEM; a *P*-value<0.05 was accepted as statistically significant. The paired *t*-test was used for within group comparisons, and one-way analysis of variance (ANOVA) was used for between group comparisons, which was followed by the Holm–Sidak method. When the data failed the normality test, ANOVA on ranks (Kruskal–Wallis) was used, followed by Dunn's method for multiple comparisons (SigmaStat.3.0).

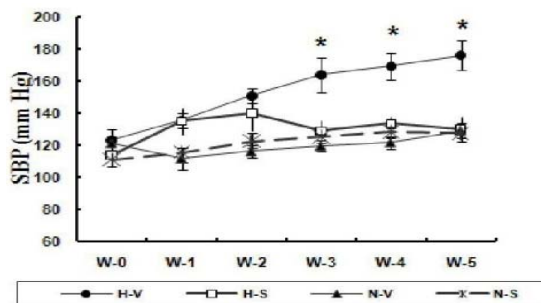
## Results

### Dietary effects of saffron on BP of normotensive and hypertensive rats

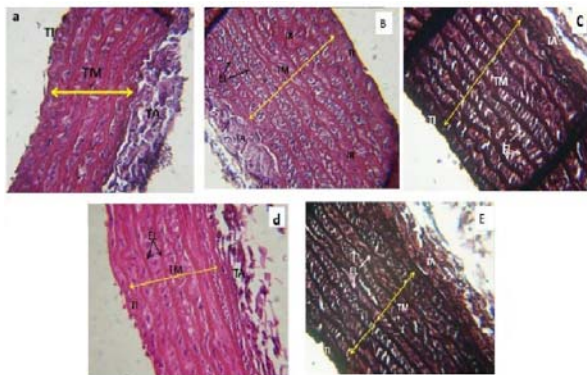
Hypertension induction significantly increased systolic BP from 123.3 to 176.14 mm Hg. Dietary saffron prevented L-NAME-induced increases in the systolic BP of hypertensive rats. This effect was clearly observed at the third week of treatment (Figure 1). Saffron and its vehicle had no effect on the systolic BP of normal rats. BP values recorded invasively at the end of the experiment were consistent with those recorded weekly with the noninvasive method.

### Dietary effect of saffron on the histomorphometry of aorta in normotensive and hypertensive rats

The tunical layer of the thoracic aorta (tunica intima, media, and adventitia) in control animals showed normal histological features. The tunica media was observed in numerous distinct lamellae, which were wavy and arranged concentrically (Figure 2a). In hypertensive rats, the aortic cross-sectional area, aortic wall thickness, and tunica media thickness were increased. The aortic wall thickening was mainly due to thickening of the tunica media. The number and thickness of concentric elastic lamellae were also increased in the tunica media (Figures 2b and 2c). Saffron extract administration (200 mg/kg/day) caused a significant reduction in the aortic cross-sectional area, the tunica media thickness, and the number of elastic lamellae in hypertensive rats (Figures 2d and 2e).



**Figure 1.** Chronic nutritional effects of saffron extract (200 mg/kg/day) on systolic blood pressure (SBP) of normal and L-NAME-induced hypertensive rats during 5 weeks (\* *P*<0.001). H-V: hypertensive + vehicle, H-S: hypertensive + saffron, N-V: Normal + vehicle, N-S: Normal + saffron, W0-5: weeks of 0-5



**Figure 2.** Representation histological sections of the thoracic aorta from a control (a), an untreated hypertensive (b & c), and saffron treated hypertensive rats (d & e). Tunica intima (TI), tunica media (TM), tunica adventitia (TA), elastic lamellae (EL), Irregularity (IR), Periodic Acid Schiff (a, b and d) and Orcein (c & e) stain,  $\times 40$

## Discussion

Dietary saffron consumed for 5 weeks had no effect on BP of normotensive rats, but it abolished L-NAME-induced increases in BP of hypertensive rats. Although L-NAME administration increased systolic BP from 123 to 176 mm Hg in control group, saffron returned it to 128.8 mmHg at 5<sup>th</sup> week of treatment. This result is consistent with that reported in the Grisolia study (12). In that study; the incidence of cardiovascular disease in Spain was lowest in regions where saffron was consumed (12). Our results also were confirmed by recent researches: the chronic IP injection of saffron stigma aqueous extract and its main constituent's safranal and crocin, reduced systolic BP of DOCA-salt induced hypertensive rats. Nevertheless saffron had no significant effect on BP of normotensive rats (8-10).

Antihypertensives are not equally effective in all rat models of hypertension, as endothelin-receptor antagonists are not effective in spontaneously hypertensive rat, but have positive effects in the DOCA-salt model. Consequently it seems that rat models of hypertension mainly share high BP, but otherwise display a wide variety of biochemical disturbances, with equally varying course and prognosis (13), so it is necessary to use different model of hypertension for precise evaluation of antihypertensive agents.

Saffron contains more than 150 active components, including crocin, picrocrocins, safranal, carotenoids, and flavonoids (1). Crocin and safranal's hypotensive effects have been reported in both normotensive and hypertensive rats and during chronic administration (4, 10). In addition, flavonoids inhibit angiotensin-converting enzyme: main target of antihypertensive agents (14). Therefore, saffron might elicit hypotension through these components in our work.

Antioxidant deficit is a basic factor in hypertensive animals. Reactive oxygen species (ROS) play a role in vascular remodeling (proliferation, migration, and hypertrophy), and consequently, in the pathology of atherosclerosis and hypertension (11). As saffron has antioxidant activity (2, 15) it might affect L-NAME-induced hypertension. Moreover, safranal acts on GABA<sub>A</sub> receptors that modulate peripheral resistance or cardiac output, which also might contribute to its hypotensive effect (4).

Hypertension induces numerous pathological changes in the cardiovascular system. Histological examination of the aorta revealed that hypertension increased the aortic area, aortic wall and media thickness, and elastic lamellae number and thickness. Saffron treatment significantly reduced most of these factors, except for aortic wall and elastic lamellae thickness. The beneficial effects of dietary saffron might induce antioxidant activity or reduce BP; however, further clarification is necessary. No change in BP or histological factors has been considered in normal rats.

In summary, the present study provides evidence that nutritional saffron prevents BP increases and aortic remodeling in the L-NAME induced hypertensive rat. These findings suggest that saffron might be useful in hypertension.

## Acknowledgment

This study was supported by a grant from Semnan University of Medical Sciences, Semnan, Iran. We are most grateful from Vice Chancellor for Research Centers, Heads of Departments of Physiology and Anatomical Sciences for support and aids. The results described in this paper were part of a student thesis.

## References

1. Kianbakht S. A systematic review on pharmacology of saffron and its active constituents. *J Med Plants* 2009; 28:1-23.
2. Kanakis CD, Tarantilis PA, Tajmir-Riahi HA, Polissiou MG. Crocetin, dimethylcrocetin and safranal bind human serum albumin: stability and antioxidative properties. *J Agric Food Chem* 2007; 55:970-977.
3. Nemati H, Boskabady MH, Ahmadzade F. Stimulatory effect of *Crocus sativus* (saffron) on  $\beta_2$ -adrenoceptors of guinea pig tracheal chains. *Phytomed* 2008; 15:1038-1045.
4. Imenshahidi M, Hosseinzadeh H, Javadpour Y. Hypotensive effect of aqueous saffron extract (*Crocus sativus* L.) and its constituents, safranal and crocin, in normotensive and hypertensive rats. *Phytother Res* 2010; 24:990-994.
5. Joukar S, Najafipour H, Khaksari M, Sepehri G, Shahrokhi N, Dabiri S, et al. The effect of saffron consumption on biochemical and histopathological heart indices of rats with myocardial infarction. *Cardiovasc Toxicol* 2010; 10:66-71.

6. Jessie SW, Krishnakantha TP. Inhibition of human platelet aggregation and membrane lipid peroxidation by food spice, saffron. *Mol Cell Biochem* 2005; 278: 59- 63.
7. Gainer JL, Jones JR. The use of crocetin in experimental atherosclerosis. *Experientia* 1975; 31:548-549.
8. Imenshahidi M, Razavi BM, Faal A, Gholampoor A, Mousavi SM, Hosseinzadeh H. The effect of chronic administration of saffron (*Crocus sativus*) stigma aqueous extract on systolic blood pressure in rats. *Jundishapur J Nat Pharm Prod* 2013; 8:175-179.
9. Imenshahidi M, Razavi BM, Faal A, Gholampoor A, Mousavi SM, Hosseinzadeh H. Effects of chronic crocin treatment on desoxycorticosterone acetate (doca)-salt hypertensive rats. *Iran J Basic Med Sci* 2014; 17:9-13.
10. Imenshahidi M, Razavi BM, Faal A, Gholampoor A, Mousavi SM, Hosseinzadeh H. The effect of chronic administration of safranal on systolic blood pressure in rats. *Iran J Pharm Res* 2015; 14:585-590.
11. Saravanakumar M, Raja B. Veratric acid, a phenolic acid attenuates blood pressure and oxidative stress in L-NAME induced hypertensive rats. *Eur J Pharmacol* 2011; 671:87-94.
12. Grisolia S. Hypoxia, saffron and cardiovascular disease. *Lancet* 1974; 2: 41-42.
13. Yigal M. Pintoa, Martin Paula and Detlev Ganten. Lessons from rat models of hypertension: from Goldblatt to genetic engineering. *Cardiovasc Res* 1998; 39:77-88.
14. Nileeka Balasuriya BW, Vasantha Rupasinghe HP. Plant flavonoids as angiotensin converting enzyme inhibitors in regulation of hypertension. *Fun Food Health Dise* 2011; 5:172-188.
15. Karimi E, Oskoueian E, Hendra R, Jaafar H. Evaluation of *Crocus sativus* L. stigma phenolic and flavonoid compounds and its antioxidant activity. *Molecules* 2010; 15:6244-6256.