

Protective effects of piperine on lead acetate induced-nephrotoxicity in rats

Sri Agus Sudjarwo ^{1*}, Koerniasari Eraiko ², Giftania Wardani Sudjarwo ³, Koerniasari ⁴

¹Department of Pharmacology, Faculty of Veterinary Medicine, Airlangga University, Surabaya 60115 Indonesia

²Department of Conservative Dentistry, Faculty of Dentistry, Airlangga University, Surabaya 60115 Indonesia

³Department of Pharmacy Biology, Faculty of Pharmacy, Hang Tuah University, Surabaya 60115 Indonesia

⁴Study Program of Environmental Health, Polytechnic of Health, Surabaya 60115 Indonesia

ARTICLE INFO	ABSTRACT
Article type: Original article	Objective(s): In this study, we investigated the protective effects of piperine on lead acetate-induced renal damage in rat kidney tissue.
Article history: Received: Jan 6, 2017 Accepted: Aug 10, 2017	Materials and Methods: Forty male rats were divided into 5 groups: negative control (rats were given aquadest daily), positive control (rats were given lead acetate 30 mg/kg BW orally once a day for 60 days), and the treatment group (rats were given piperine 50 mg; 100 mg and 200 mg/kg BW orally once a day for 65 days, and on 5 th day, were given lead acetate 30 mg/kg BW one hr after piperine administration for 60 days). On day 65 levels of blood urea nitrogen (BUN), creatinine, malondialdehyde (MDA), Superoxide Dismutase (SOD), and Glutathione Peroxidase (GPx) were measured. Also, kidney samples were collected for histopathological studies.
Keywords: Antioxidants Lead acetate Nephrotoxicity Piperine Protective	Results: The results revealed that lead acetate toxicity induced a significant increase in the levels of BUN, creatinine, and MDA; moreover, a significant decrease in SOD and GPx. Lead acetate also altered kidney histopathology (kidney damage, necrosis of tubules) compared to the negative control. However, administration of piperine significantly improved the kidney histopathology, decreased the levels of BUN, creatinine, and MDA, and also significantly increased the SOD and GPx in the kidney of lead acetate-treated rats.
	Conclusion: From the results of this study it was concluded that piperine could be a potent natural herbal product exhibiting nephroprotective effect against lead acetate induced nephrotoxicity in rats.

► Please cite this article as:

Sudjarwo SA, Eraiko K, Wardani Sudjarwo GW, Koerniasari. Protective effects of piperine on lead acetate induced-nephrotoxicity in rats. Iran J Basic Med Sci 2017; 20:1227-1231. doi: 10.22038/IJBMS.2017.9487

Introduction

Lead acetate is a biotoxic environmental and industrial pollutant, which accumulates in almost all body tissues such as the liver, lung, bones, kidneys, reproductive organs, and the immune system (1). The physiological, biochemical, and behavioral effects of this toxic lead in animals has been reported, including disorders of central and peripheral nervous systems (2), cardiovascular system (3), kidney (4), liver (5), and the reproductive system (6).

The mechanism for lead nephrotoxicity is oxidative stress and there is an imbalance between the scavenging capacity of antioxidants and the generation of reactive oxygen species (ROS) in the kidney (7,8). Recent studies show ROS or free radicals such as superoxide ion (O₂⁻), hydroxyl radical (OH⁻), and nitrogen oxide (NO) have a pivotal role in lead-induced nephrotoxicity (9, 10). MDA may be used as an indicator of cell membrane damage after exposure to ROS and free radicals.

The increase in MDA levels in kidney suggests that antioxidant failure to inhibit ROS and formation of free radicals can enhance lipid peroxidation causing nephrotoxicity (11, 12). The MDA level is the direct evidence of tissue injury processes caused by free radicals (13, 14).

Mervat *et al.* (2012) have reported that antioxidant activity or inhibition of generation of free radicals plays a crucial role in protection against heavy metal induced-nephrotoxicity (10). So, it has been claimed that protective agents against free radicals, such as antioxidants, may be useful therapeutics for heavy metal toxicity in the kidneys.

Natural products or medicinal plants having antioxidant properties for reducing free radical-induced tissue damage has been reported. Medicinal plants have advantages over the conventionally used drugs, which are very expensive and known to have harmful side effects for the treatment of various diseases (15).

*Corresponding author: Sri Agus Sudjarwo. Department of Pharmacology, Faculty of Veterinary Medicine, Airlangga University, Surabaya, Indonesia. Tel: 62856450006; email: ags158@yahoo.com

Many authors tried medical plant antioxidants like quercetine, curcumin, and catechin against lead toxicity (10,16,17). Several studies have shown that obtained piperine from *Piper longum* L and *Piper nigrum* L has remarkable biological activities such as antioxidant (18), anti-inflammatory, analgesic (19), antihypertensive (20), antitumoral (21), and antibacterial (22). In the present study, the protective effects of piperine were investigated on lead acetate-induced renal damage in rat kidney tissue.

Materials and Methods

Chemicals

Lead acetate and piperine were purchased from Sigma-Aldrich (USA; Cat No 6080-56-4 and 458-37-7, respectively). Malondialdehyde assay kit was obtained from NWLSS (USA; Cat. No. NWK-MDA01). Determination of SOD and GPx tissue levels were conducted using assay kits from Cayman Chemicals (USA; Cat. No. 706002 and 703102, respectively).

Experimental animal

Male Wistar rats weighing approximately 200–250 g (2.5–3 months old) were obtained from Gadjah Mada University, Yogyakarta, Indonesia for experimental purpose. They were housed in plastic cages in an air-conditioned room with temperature maintained at $26^{\circ}\text{C} \pm 2^{\circ}\text{C}$ and 12 hr in alternating light and dark cycles. The rats were given ad libitum feed and drink water. This study was reviewed by the Ethical Clearance Committee for Preclinical Research, Institute of Tropical Disease, Airlangga University, Indonesia and obtained ethical clearance under No. 190/ITD/12/2015.

Experimental design

The sample used 40 male rats divided into 5 groups: negative control (rats were given aquadest daily), positive control (rats were given lead acetate 30 mg/kg BW orally once a day for 60 days), and the treatment group (rats were given piperine 50 mg, 100 mg, 200 mg/kg BW orally once a day for 65 days, and on the 5th day, were given lead acetate 30 mg/kg BW one hr after piperine administration for 60 days). On day 65, blood samples were taken by cardiac puncture into tubes and centrifuged at 3000 rpm for 20 min, and then serum levels of BUN, creatinine, MDA, SOD, and GPx were measured. Kidneys were homogenized in 50 mM sodium phosphate buffer (pH 7.4) containing 0.1 mM ethylenediaminetetraacetic acid (EDTA) at 4 °C. The supernatant was separated by centrifugation at 1000 rpm for 20 min at 4 °C. The supernatant was used for the analysis of SOD and GPx. Kidneys were fixed in formalin 10% for histopathological study.

Biochemical assays

Serum biochemical marker activities of BUN, creatinine, MDA, and enzymatic antioxidants (SOD and GPx) were assessed in the kidney.

Measurement of blood urea nitrogen was conducted by the diacetyl monoxime method (23). The protein-free filtrate was made by adding serum and an equal amount of trichloroacetic acid 10%, then the mixture was centrifuged at 2000 rpm, and 0.5 ml supernatant was taken and added to 3.5 ml of water, 0.8 ml diacetyl monoxime 2%, and 3.2 ml sulphuric acid-phosphoric acid reagent (reagent was made by adding 150 ml 85% phosphoric acid, 140 ml water, and 50 ml of sulphuric acid). Furthermore, the reaction mixture was incubated for 30 min in a boiling water bath and then cooled to room temperature using cold tap water. The spectrophotometer absorbance was read at the wavelength of 480 nm.

Measurement of creatinine was conducted by the alkaline picrate method (23). The protein-free filtrate was made by mixing 1.0 ml serum, 1.0 ml sodium tungstate (5%), 1 ml sulfuric acid (0.6 N), and 1 ml water, and then centrifuged at 800 rpm for 5 min. The supernatant was added to a mixture containing 1 ml picric acid (1%) and 1 ml sodium hydroxide (0.75 N). The spectrophotometer absorbance was read at the wavelength of 520 nm.

Lipid peroxidation in the serum was estimated by the formation of MDA and measured by the thiobarbituric reactive (TBARS) method (24). By adding 150 µl serum sample into 1 ml trichloroacetic acid 17.5%, 1 ml TBA 0.66%, mixed by vortex, incubated for 15 min in a boiling water bath, and then cooled to room temperature. Then 1 ml trichloroacetic acid 70% was added and mixed at room temperature for 20 min, centrifuged at 2000 rpm for 15 min; the supernatant was taken out for reading with a spectrophotometer at 532 nm.

Portions of the kidney were immediately washed in ice-cold physiological saline and homogenized in 50 mM potassium phosphate (pH 7.4) to render 10% homogenate. The homogenate was centrifuged at 4000 rpm at 4 °C for 15 min. The supernatant was used for SOD and GPx analysis (25).

Histopathological study

The kidneys obtained from each group were kept in 10% formalin solution. Then fixed kidneys were embedded in paraffin and serial sections were cut for histopathological examination and stained with hematoxylin and eosin. The stained sections were examined under a light microscope.

Statistical analysis

All data were expressed as means \pm standard deviation. One-way ANOVA was used for the analysis, and LSD was performed to compare the groups (SPSS version 17.0).

Results

Effects of piperine on lead acetate induced changes in the serum BUN, creatinine, and MDA. An increase in the serum BUN and creatinine indicates kidney damage. Analysis of BUN and creatinine was

performed to evaluate piperine in lead acetate treated rats. The positive control group (lead acetate treated rats) showed significant ($P<0.05$) increase in serum BUN, creatinine, and MDA levels compared with the negative control group. In contrast, the groups pretreated with piperine (200 mg/kg BW) showed significantly ($P<0.05$) decreased serum BUN, creatinine, and MDA levels in a dose-dependent manner with respect to the positive control towards normalization and close to the negative control group (Table 1).

Effects of piperine on lead acetate induced changes in SOD and GPx

Lead acetate enhances the intracellular formation of ROS causing kidney damage. In the present study, we analyzed the kidney levels of two antioxidants (SOD and GPx). Positive controls (lead acetate treated rats) showed significant ($P<0.05$) decrease in the levels of SOD and GPx compared with the negative controls. Groups pretreated with piperine (200 mg/kg BW but not 50 mg/kg BW and 100 mg/kg BW) showed a significant ($P<0.05$) increase in the levels of SOD and GPx compared with the lead acetate treated rats towards the normal level and close to the negative control (Table 2).

Table 1. Effects of piperine on lead acetate induced changes in the serum blood urea nitrogen, creatinine, and malondialdehyde

Groups	Means ± Standard Deviation		
	Blood Urea Nitrogen (mmol/l)	Creatinine (mmol/l)	Malondialdehyde (nmol/l)
Negative Control	8.21 ^a ± 1.23	32.63 ^a ± 4.85	5.83 ^a ± 0.75
Positive Control	25.17 ^b ± 2.41	65.33 ^b ± 7.91	10.14 ^b ± 0.87
Piperine 50 mg/kg BW	27.31 ^b ± 4.63	68.30 ^b ± 6.51	9.74 ^b ± 1.12
Piperine 100 mg/kg BW	21.62 ^b ± 3.92	61.20 ^b ± 7.15	8.92 ^b ± 0.89
Piperine 200 mg/kg BW	14.57 ^c ± 4.23	41.80 ^c ± 5.15	6.12 ^c ± 0.42

a,b,c Different superscripts within each column indicate significant difference between the means ($P<0.05$)

Table 2. Effects of piperine on lead acetate induced changes in superoxide dismutase and glutathione peroxidase

Groups	Means ± Standard Deviation	
	Superoxide Dismutase (U/mg)	Glutathione Peroxidase (U/mg)
Negative Control	36.32a ± 3.05	46.63a ± 6.31
Positive Control	16.89b ± 1.72	28.35b ± 3.92
Piperine 50 mg/kg BW	17.43b ± 1.42	30.29b ± 4.13
Piperine 100 mg/kg BW	19.29b ± 2.89	32.81b ± 5.17
Piperine 200 mg/kg BW	28.37c ± 3.14	40.38d ± 3.55

a, b, c Different superscripts within each column indicate significant difference between the means ($P<0.05$)

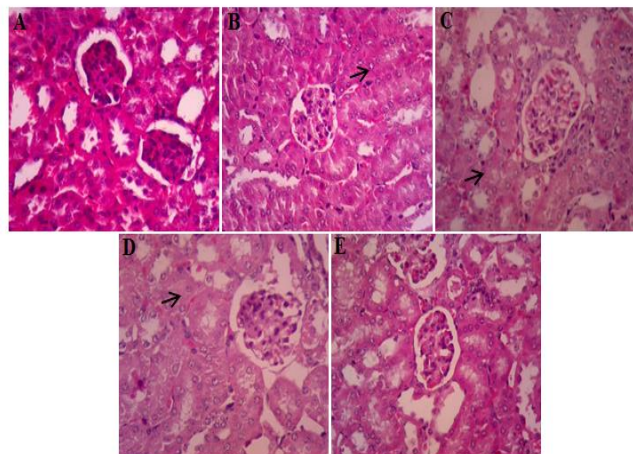


Figure 1. Histological study of pretreatment with piperine on lead acetate induced nephrotoxicity. Normal morphology of renal sections in the negative control group (A). The lead acetate treated group showed necrosis in tubules (indicated by arrows) (B). Rats treated with piperine 50 mg/kg BW and 100 mg/kg BW showed necrotic changes (C and D). Rats treated with piperine 200 mg/kg BW showed regeneration in tubular epithelial cells (E). H&E ×400

Effects of piperine on lead acetate induced kidney injury

Histopathological study was performed using light microscopy. Microscopic examination of normal kidney showing intact tubules and glomerulus. In the lead acetate treated group, renal tissues showed tubular necrosis of kidneys indicating cell damage. Pretreatment with piperine 200 mg/kg BW but not 50 mg/kg BW or 100 mg/kg BW significantly prevented histopathological changes towards normal (Figure 1).

Discussion

Lead is one of environmental contaminants and industrial pollutants, producing severe organ damage in animals and humans. Studies have shown that the kidney is one of the primary targets in lead associated toxicity (7, 26). Lead produces oxidative damage in the kidney by enhancing lipid peroxidation and causes kidney dysfunction and increases free radical damage (14, 27). Antioxidant enzyme levels are used as markers of oxidative stress in heavy metal toxicity. Based on the present study lead-induced toxicity might inhibit tissue activities of antioxidants SOD and GPx. The examined tissues of rats indicate that the decrease of SOD and GPx activities might result from oxidative stress because these enzymes catalyze the decomposition of ROS (9, 28). The levels of these antioxidants might provide a clear indication of the extent of cytotoxic damage that occurs in kidney tissues. Therefore, some authors have postulated that antioxidants should be one of the important components of effective treatment of lead poisoning (7, 26).

Recently, many natural products and herbs are used for research; due to their high therapeutic

potential and low price with little side effects compared with synthetic drugs, the present study investigated the nephroprotective effect of piperine.

Most of the scientific research has been focused on phytochemical studies in order to find novel drugs. Pharmacodynamic and pharmacokinetic studies are scarcely available. From phytochemical studies, *P. longum* and *P. nigrum* consist of more than 90% piperine. These piperines are of great interest due to phytochemical and pharmacological properties, such as antioxidant (18), anti-inflammatory, analgesic (19), antihypertensive (20), antitumoral (21), and antibacterial activities (22).

The purpose of this study was to observe the protective effects of piperine on renal damage of rats that were given lead acetate. The lead acetate significantly increased creatinine and BUN levels, which can be an indicator of impaired renal function in nephrotoxicity. The serum creatinine and BUN are recommended for the assessment of kidney injury in preclinical studies as it is considered a more specific and sensitive indicator of kidney damage. Low levels of serum creatinine and BUN are normally found in the blood, but when the kidney is damaged or diseased, creatinine and BUN levels go up. Most increases in serum creatinine and BUN levels are caused by kidney damage (29). The present study showed increasing creatinine and BUN levels in the kidney damaged rats that were given lead acetate in comparison to the negative controls. A similar observation was reported by Hussein *et al.* (8), who reported that lead acetate treatment induced significant elevation of serum creatinine and BUN activities. Our results indicated that piperine has a nephroprotective activity against lead acetate-induced nephrotoxicity, where the pretreated groups with piperine 200 mg/kg b.w, showed an improvement in the creatinine and BUN levels. This might be through its direct action on free radicals of lead acetate, protecting the kidney from cellular damage by maintaining its membrane integrity.

MDA is the final product of lipid peroxidation and the direct depletion of antioxidant reserves on lead toxicity induces the oxidative stress (28). The present investigation results show significantly increased MDA levels in the kidneys of rats that were given lead acetate in comparison to the negative controls. This result suggested that lead acetate can increase the oxidative stress in rats. Therefore, the significantly decreased levels of MDA in the tissues of piperine treated groups, as compared with the lead acetate group, indicate attenuation of lipid peroxidation. It has been reported that lead acetate induced oxidative stress tissue injury through increased generation of ROS and by causing direct depletion of antioxidant reserves (7, 12). The consequences of oxidative stress of lead acetate toxicity result in increased lipid peroxidation that may cause more severe oxidative

damage in the tissues (15, 18). The effect of piperine as a powerful antioxidant and free radical scavenger may decrease MDA levels in the kidney of lead-treated rats. The administration of piperine at a dose of 200 mg/kg body weight decreased the MDA levels when rats were given lead acetate. This means that piperine minimized the toxic effect of lead acetate via its antioxidant activity. The antioxidant protective mechanism scavenges the free radicals and decreases the oxidative stress, which is responsible for kidney damage and thus inhibits the lipid peroxidation (MDA). The results suggested that piperine could inhibit oxidative stress by decreasing the MDA levels in rats that were treated with lead acetate. A similar result has shown that vitamin C and vitamin E enhanced the antioxidant status and inhibited lipid peroxidation (MDA) in rats with lead acetate induced kidney injury. These findings indicate that the antioxidant activity of vitamin C and vitamin E is targeted primarily towards the lipid components of cells. Antioxidants such as vitamin C and vitamin E have been reported to inhibit free radical formation and are effective in minimizing lipid peroxidation in several different organs (15).

SOD and GPx are important antioxidant enzymes. They have an important role against ROS. SOD is a metalloenzyme that catalyzes superoxide radicals (O₂⁻) to oxygen and nonreactive compounds such as H₂O₂. GPx is an intracellular antioxidant enzyme that enzymatically reduces hydroperoxide and H₂O₂ to limit its toxic effects. Furthermore, this enzyme can be used to inhibit oxidative stress in cells. It has been reported that lead binds to sulfhydryl proteins in several enzymes such as SOD and GPx, which can alter antioxidant activities by inhibiting functional SH groups in these enzymes (7). The present study shows that the activity of SOD and GPx in rat kidneys was inhibited by lead acetate treatment. These results are in accordance with previous research (14). This suggested that lead acetate toxicity can inhibit the activity of the antioxidant enzymes (SOD and GPx) that can cause oxidative stress. The administration of piperine decreased the accumulation of free radicals, which might increase the activities of SOD and GPx in the kidney of lead-treated rats. Piperine acts as a scavenger for the oxygen-derived free radicals, thus protecting against cellular damage.

Histopathological results showing structural changes in the renal tissue of aminoglycoside metal toxins such as lead acetate were reported by some researchers. Histopathological view of renal sections in the lead acetate treated group showed necrosis in tubules, as compared to the negative control group. Necrosis tubular epithelial changes were considerably mild in the groups treated with piperine 100 mg/kg while rats treated with 200 mg/kg piperine showed regeneration in tubular epithelial cells. We think that morphological changes in kidneys tended

to be considerably mild in lead acetate plus piperine treatment.

Conclusion

It could be concluded that piperine through its antioxidant mechanisms as a scavenger for the oxygen-derived free radicals protects from lead-induced kidney damage in rats. Piperine can be a future natural product for counteracting the lead acetate intoxication.

These results showed that piperine has a potential nephroprotective effect in a dose-dependent manner that minimizes or diminishes compounds with nephrotoxic effect induced by lead acetate toxicity.

Acknowledgment

We are gratefully thankful to Polytechnic of Health, Ministry of Health, Indonesia for supporting this study.

Conflict of interest

There are no conflicts of interest in this article.

References

- Gagan F, Deepesh G, Archana T. Toxicity of lead: A review with recent updates. *Interdiscip Toxicol* 2012; 5:47-58.
- Ani M, Aparajita C, Rituparna G, Mahitosh S. Protective effects of selenium and zinc on the brain acetyl cholinesterase activity in lead intoxicated rat. *Res Pharm Sci* 2006; 2:80-84.
- Vaziri ND, Gonick HC. Cardiovascular effects of lead exposure. *Indian J Med Res* 2008;128:426-435.
- Jia Q, Ha X, Yang Z, Hui L, Yang X. Oxidative stress: a possible mechanism for lead-induced apoptosis and nephrotoxicity. *Toxicol Mech Methods* 2012; 22:705-710
- Mohamed OI, El-Nahas AF, El-Sayed YS, Ashry KM. Ginger extract modulates Pb-induced hepatic oxidative stress and expression of antioxidant gene transcripts in rat liver. *Pharm Biol* 2015:1-9
- Adhikari NN, Sinha R, Narayan, Saxena DK. Lead-induced cell death in testes of young rats. *J Appl Toxicol* 2001;21:275-277.
- Patrick L. Lead toxicity part II: The role of free radical damage and use of antioxidants in the pathology and treatment of lead toxicity. *Altern Med Rev* 2006; 11:114-127.
- Hussein SA, Mohammed RR, Ali AH, Protective effects of alpha-lipoic acid against lead-induced oxidative stress in erythrocytes of rats. *Benha Vet Med J* 2014; 27: 382-395.
- Xu J, Lian LJ, Wu C, Wang XF, Fu WY. Lead induces oxidative stress, DNA damage and alteration of p53, Bax and Bcl-2 expressions in mice. *Food Chem Toxicol* 2008; 46:1488-1494.
- Mervat HG, Nabela IE, Mohamed MAH, Gihan GM. Efficacy of Curcumin on Lead Induced Nephrotoxicity in Female Albino Rats. *J Am Sci* 2012; 8:78-82.
- Kosem N, Han YH, Moongkarndi P. Antioxidant and cytoprotective activities of methanolic extract from *Garcinia mangostana* Hulls. *Science Asia* 2007; 33: 283-292.
- Ibrahim NM, Eweis EA, El-Beltagi HS, Abdel Mobdy YE. Effect of lead acetate toxicity on experimental male albino rat. *Asian Pac J Trop Biomed* 2012;2: 41-46.
- Jackie T, Haleagrahara N, Chakravarthi S. Antioxidant effects of *Etlingera elatior* flower extract against lead acetate induced perturbations in free radical scavenging enzymes and lipid peroxidation in rats. *BMC Research Notes* 2011; 4:67-75.
- Wang J, Yang Z, Liu L, Xuezhong Liu ZL. Protective effect of naringenin against lead-induced oxidative stress in rats. *Biol Trace Elem Res* 2012; 146:354-359.
- Aziz FM, Maulood IM, Chawsheen MA. Effects of melatonin, vitamin C and E alone or in combination on lead-induced injury in liver and kidney organs of rats. *Pakistan J Zool* 2014; 46: 1425-1431.
- Chen L, Yang X, Jiao H. Tea catechins protect against lead-induced ROS formation, mitochondrial dysfunction, and calcium dysregulation in PC12 cells. *Chem Res Toxicol* 2003; 16:1155-1161.
- Hanan M, El-Latief A. Protective effect of quercetin and or zinc against lead toxicity on rat testes. *Global J Pharmacol* 2015; 9: 366-376.
- Yadala P, Viswanathswamy AHM. *In vitro* antioxidant and cytotoxic activity of rutin and piperine and their synergistic effect. *Int J Pharm Pharm Sci* 2016; 8: 78-82.
- Sudjarwo SA. The potency of piperine as antiinflammatory and analgesic in rats and mice. *Folia Medica Indonesiana* 2005; 41:190-194.
- Taqvi SI, Gilani AH. Blood pressure lowering and vasomodulator effects of piperine. *J Cardiovasc Pharmacol* 2008; 52:452-458.
- Doucette CD, Hilchie AL. Piperine, a dietary phytochemical, inhibits angiogenesis. *J NutrBiochem* 2013; 24:231-239.
- Sharma S, Kalia NP, Suden P. Protective efficacy of piperine against *Mycobacterium tuberculosis*. *Tuberculosis* 2014;94:389-396.
- Aslam M, Ahmad ST, Dayal R, Nafees S, Singh S. Nephroprotective action of *Peucedanum grande* against cadmium chloride induced renal toxicity in wistar rats. *Excli J* 2012; 11:444-452.
- Suji Arivazhagan JJ, Vimalastalin R. Nephroprotective activity of *Aristolochia indica* leaf extract against gentamicin induced renal dysfunction. *Inter J of Res in Biochem Biophysics* 2014; 4:13-18.
- Hamadouche NA, Lazeb H, Kaddouri A, Aoues A, Ameliorated effects of Green tea extract on lead induced kidney toxicity in rats. *Algerian J Nat Prod* 2015; 3:130-137.
- Hsu PC, Guo YL. Antioxidant nutrients and lead toxicity. *Toxicology* 2002; 180:33-44.
- Ishiaq O, Adeagbo AG, Henshaw N. Effect of a natural antioxidant fruit - tomatoes (*Lycopersicon esculentum*) as a potent nephroprotective agent in lead induced nephrotoxicity in rat. *J. Pharmacog. Phytother* 2011; 3:63-66.
- Newairy AS, Abdou HM. Protective role of flax lignans against lead acetate induced oxidative damage and hyperlipidemia in rats. *Food Chem Toxicol* 2009; 47:813-818.
- Moussa SA, Bashandy SA. Biophysical and biochemical changes in the blood of rats exposed to lead toxicity. *Rom J Biophys* 2008;18:123-133.