

# Rutin mitigates perfluorooctanoic acid-induced liver injury via modulation of oxidative stress, apoptosis, and inflammation

Maloos Naderi<sup>1,2</sup>, Mohammad Seyedabadi<sup>1,3</sup>, Fereshteh Talebpour Amiri<sup>4</sup>, Sholeh Akbari<sup>1,2</sup>, Fatemeh Shaki<sup>1,5\*</sup>

<sup>1</sup> Department of Toxicology and Pharmacology, Faculty of Pharmacy, Mazandaran University of Medical Sciences, Sari, Iran

<sup>2</sup> Student Research Committee, Mazandaran University of Medical Sciences, Sari, Iran

<sup>3</sup> Pharmaceutical Sciences Research Center, Faculty of Pharmacy, Mazandaran University of Medical Sciences, Sari, Iran

<sup>4</sup> Department of Anatomy, Molecular, and Cell Biology Research Center, Faculty of Medicine, Mazandaran University of Medical Sciences, Sari, Iran

<sup>5</sup> Pharmaceutical Sciences Research Center, Hemoglobinopathy Institute, Mazandaran University of Medical Sciences, Sari, Iran

## ARTICLE INFO

### Article type:

Original

### Article history:

Received: Dec 24, 2022

Accepted: Jul 2, 2023

### Keywords:

Apoptosis

Hepatotoxicity

Inflammation

Oxidative stress

Perfluorooctanoic acid

Rutin

## ABSTRACT

**Objective(s):** Perfluorooctanoic acid (PFOA) is a persistent organic pollutant (POP), broadly present in the environment. Due to long biological half-life, it is accumulated in the body, especially the liver, causing hepatocellular damage. This study was designed to assess the effects of rutin on PFOA-induced liver damage in rats.

**Materials and Methods:** Male Wistar rats were exposed to PFOA (10 mg/kg/day) alone, or in combination with different doses of rutin (25, 50, and 100 mg/kg/day) by oral gavage for 4 weeks.

**Results:** PFOA altered the levels of liver enzymes, induced a notable change in the tissue structure of the liver, caused some levels of mitochondrial dysfunction, and increased the expression of pro-apoptotic and pro-inflammatory genes. Co-treatment with rutin mitigated the PFOA-induced elevation of liver enzymes, histopathological defects, oxidative damage, and mitochondrial dysfunction. In addition, rutin declined the stimulatory effects of PFOA on the Bax: Bcl2 ratio and reduced the PFOA-induced gene expression of TNF- $\alpha$ , IL-6, NF- $\kappa$ B, and JNK.

**Conclusion:** These findings suggest rutin as a protective agent for PFOA-induced liver injury, albeit the protection was partial. Possible mechanisms are inhibition of oxidative stress, mitochondrial dysfunction, and inflammatory response.

► Please cite this article as:

Naderi M, Seyedabadi M, Talebpour Amiri F, Akbari Sh, Shaki F. Rutin mitigates perfluorooctanoic acid-induced liver injury via modulation of oxidative stress, apoptosis, and inflammation. Iran J Basic Med Sci 2023; 26:

## Introduction

Perfluorooctanoic acid (PFOA), as a stable synthetic organic compound, is extensively used for the production of a large variety of consumer products and industrial processes (1). PFOA, due to carbon-fluorine bonds, is extremely resistant to environmental degradation and is accumulated in the food chain, causing the greatest ecological concern (2). Previous research confirmed that exposure to PFOA results in various toxicities (3). In this regard, the liver is the major organ for the accumulation as well as toxicity of PFOA, albeit the exact mechanisms are yet to be elucidated.

Oxidative stress (4) and mitochondrial dysfunction (5) are the main mechanisms by which environmental pollutants can cause liver injury. In fact, xenobiotics induce mitochondrial dysfunction, leading to excessive production of reactive oxygen species (ROS), loss of mitochondrial membrane potential, and finally apoptosis (6). Recent studies have verified that PFOA causes cellular damage and mitochondrial defect in pancreatic  $\beta$ -cells (7).

Inflammation is another theory associated with hepatotoxic response (8-10). Exposure to PFOA elevates the production of pro-inflammatory cytokines such as IL-6 and TNF- $\alpha$  (11). Nuclear Factor Kappa B (NF- $\kappa$ B), the main transcriptional regulator of inflammation, is also involved in stress response and innate immunity. Its activation leads

to the transcription of genes involved in the synthesis of inflammatory cytokines (12, 13). c-Jun-N-terminal kinase (JNK) is also linked to NF- $\kappa$ B and plays a significant role in inflammatory responses (12). Multiple stimuli associated with inflammation (for instance, TNF- $\alpha$ , IL-1, and oxidative stress) activate both JNK/AP-1 and NF- $\kappa$ B (14, 15).

Rutin (3-rhamnopyranosyl-glucosyl quercetin), is a flavonoid glycoside abundantly found in certain vegetables and fruits (16). The antioxidant and anti-inflammatory properties of rutin are shown to protect vital organs from the deleterious effects of ROS (17). In particular, rutin binds to iron ions, and inhibits the interaction of hydrogen peroxide in Fenton reaction, thus preventing one of the key steps in the production of reactive free radicals (18). Rutin attenuated isoniazid-induced liver injury via inhibition of oxidative stress (19). The current investigation was designed to evaluate the potential protective effects of rutin on PFOA-induced hepatotoxicity and its possible molecular mechanisms by assessing oxidative stress, mitochondrial dysfunction, and inflammation in male rats.

## Materials and Methods

### Animal treatment and experimental design

PFOA and rutin were purchased from Sigma Aldrich (St. Louis, MO, USA). PFOA was dissolved in water and

\*Corresponding author: Fatemeh Shaki. Department of Toxicology and Pharmacology, Faculty of Pharmacy, Mazandaran University of Medical Sciences, Sari, Iran; Pharmaceutical Sciences Research Center, Hemoglobinopathy Institute, Mazandaran University of Medical Sciences, Sari, Iran. Email: fshaki.tox@gmail.com

administered orally by gavage at the dose of 10 mg/kg, as reported in previous studies (20) with some changes based on our pre-test data. The dose of rutin used in this study was determined according to previous studies (17). Rutin was dissolved in 1% DMSO and administered orally by gavage for 1 hr prior to PFOA administration.

Male Wistar rats (200-250 g) were obtained from the Laboratory Animal Research Center of Mazandaran University of Medical Sciences, Sari, Iran. All experimental procedures were approved by the ethical committee of Mazandaran University of Medical Sciences, Sari, Iran (Ethical code: IR.MAZUMS.REC.1399.6354). After acclimatization, rats were randomly divided into seven groups (n=6), and treated once daily by gavage for 4 weeks as follows: 1) control (normal saline); 2) rutin (100 mg/kg); 3) PFOA (10 mg/kg); 4-6) PFOA (10 mg/kg)+different doses of rutin (25, 50, and 100 mg/kg); and 7) PFOA (10 mg/kg)+vitamin C (100 mg/kg) as a positive control.

At the end of treatment, the animals were anesthetized (xylazine 5 mg/kg and ketamine 80 mg/kg), and blood samples were collected for biochemical assays. The liver was separated and split into three parts and stored in suitable conditions for histopathological, gene expression, and mitochondrial studies (21).

#### Serum biochemical evaluation

The serum levels of alanine transaminase (ALT) and aspartate aminotransferase (AST) were estimated by employing commercial standard kits (Pars Azmun, Iran) with Alpha-Classic Auto Analyzer.

#### Histopathological examination

Liver samples were fixed, processed, sectioned, and stained with hematoxylin and eosin (H&E) according to the protocols described in our previous study. The degree of liver injury was then determined under light microscopy. Liver damage was determined as the sum of all manifestations (22).

#### Assessment of oxidative stress in liver tissue

##### Total protein

Protein concentrations were determined in samples through the Coomassie Blue protein binding Bradford method (23).

##### Liver oxidative stress

##### Reactive oxygen species (ROS)

The study measured intracellular levels of ROS in liver homogenates using the dichlorodihydro- fluorescein diacetate (DCFH-DA) dye as an indicator. The liver homogenate was diluted with phosphate-buffered saline (PBS) to a ratio of 1:20 (v/v), followed by mixing 190  $\mu$ l of the homogenate with 10  $\mu$ l of 1 mM DCFH-DA. After incubating for 30 min at 37 °C, the conversion of DCFH-DA to 2', 7'-dichlorofluorescein was measured using a JASCO FP-6200 spectrofluorometer at excitation/emission wavelengths of 485/520 nm, respectively. ROS concentration was reported as fluorescent intensity per 1 mg protein (24).

##### Lipid peroxidation (LPO)

Malondialdehyde (MDA) formation was determined as an indicator for lipid peroxidation, utilizing thiobarbituric acid (TBA) as a marker. The absorbance of the supernatant

was measured using an ELISA reader at the wavelength of 532 nm (Tecan, Rainbow Thermo, Austria) to evaluate the quantity of MDA formation. The standard is Tetramethoxypropane and results were expressed as micromolar ( $\mu$ M)/mg protein (25).

##### Protein carbonyl (PrC)

The protein carbonyl level was evaluated by the spectrophotometric method at 365 nm. Briefly, samples were treated with TCA and incubated at 4 °C for 15 min. The precipitates were incubated with 2,4-dinitrophenylhydrazine (DNPH) at room temperature for 1 hr, while vortexing was performed every 5 min. After protein precipitation and dissolution in guanidine hydrochloride, the carbonyl content was measured at 365 nm (26).

##### Reduced glutathione reduction (GSH)

Estimation of reduced glutathione content in liver tissue homogenates was performed using dithiobis (2-nitrobenzoic acid) (DTNB) as an indicator, and the yellow color that developed was read at 412 nm on a spectrophotometer (UV-1601 PC, Shimadzu, Japan). The results were expressed in  $\mu$ M/mg protein (27).

##### Superoxide dismutase (SOD) activity

SOD activity assay was measured using Nasdox commercial kit (Navard Salamat Co, Iran). The assay is based on the inhibition of the oxidation of pyrogallol, which is normally oxidized in the presence of o-2. The presence of SOD inhibits the autooxidation of pyrogallol, allowing for indirect assessment of enzyme activity using a spectrophotometer at 405 nm (26). In essence, the activity of SOD was quantitatively determined using a commercially available kit that measures the inhibition of pyrogallol oxidation (26).

##### Nitric oxide (NO) level

The concentration of nitric oxide was measured using a rat-specific ELISA kit (Cib Zist Fan Co., Iran) based on the Griess reaction. In the first step, nitrite reacts with sulfanilic acid to form diazonium ions. In the second step, these ions are combined with N-(1-naphthyl) ethylene diamine, resulting in the formation of a pink-colored azo compound. This reaction is well-established in scientific literature and has been previously described (26).

#### Mitochondrial function

##### Mitochondrial viability

Mitochondrial viability was assayed using 3-(4,5-dimethylthiazol-2-yl)-2,5-diphenyltetrazolium bromide (MTT). Briefly, MTT (0.4%) was added to 100  $\mu$ l of fresh isolated mitochondrial suspensions (1 mg protein/ml) and then incubated at 37 °C for 30 min. The plate was read at 570 nm after dissolution of purple formazan crystals with DMSO (26, 28).

##### Mitochondrial membrane potential (MMP)

The measurement of mitochondrial membrane potential (MMP) was determined by the uptake of cationic fluorescent dye, rhodamine-123, into the mitochondria. To conduct the MMP assay, a mitochondrial fraction solution containing 1 mg protein/ml was prepared with the addition of 10  $\mu$ M rhodamine 123 in MMP assay buffer, which consisted of

various components such as sucrose, D-mannitol, KCl,  $\text{KH}_2\text{PO}_4$ ,  $\text{MgCl}_2$ , EGTA, sodium succinate, HEPES, and rotenone. The fluorescence intensity of rhodamine released outside the mitochondria was detected using a fluorescence spectrophotometer (Shimadzu RF5000U) at the excitation and emission wavelengths of 490 nm and 535 nm, respectively. An increase in fluorescence intensity indicates a decrease in MMP.(29, 30).

#### Mitochondrial swelling

The evaluation of mitochondrial swelling was carried out by observing changes in light scattering measured at 540 nm using a spectrophotometer. Initially, freshly isolated mitochondria were suspended in a buffer designed to promote swelling, which consisted of 70 mM sucrose, 230 mM mannitol, 3 mM HEPES, 2 mM Tris-phosphate, 5 mM succinate, and 1  $\mu\text{M}$  rotenone. The absorbance of the mitochondrial suspension was measured using an ELISA reader manufactured by Tecan; Rainbow Thermo, Austria. A decrease in absorbance is accompanied by an increase in mitochondrial swelling (26).

#### RNA extraction and real-time polymerase chain reaction (RT-PCR)

Total RNA was extracted from liver tissue using Hybrid-R™ total RNA isolation kit (Denazist, Iran) according to the manufacturer's instructions. cDNA synthesis was accomplished using a Pars-Tous commercial kit (31, 32). Real-time PCR was performed with specific primers (list in supplementary file) for each gene using Corbett Rotor-Gene 6000 (Qiagen, Germany) and normalized to glyceraldehyde-3-phosphate dehydrogenase (GAPDH) levels, with the  $2^{-\Delta\Delta\text{CT}}$  method (33).

#### Statistical analysis

The mean and standard deviation (SD) were used to express the data. Statistical analysis was performed using one-way ANOVA with Tukey's *post hoc* test for parametric variables and Kruskal-Wallis H test for non-parametric data. The Shapiro-Wilk test was employed to assess the normality assumption. GraphPad Prism version 8 was utilized for both data presentation and analysis and statistical significance was considered at  $P$ -value < 0.05.

**Table 1.** Effect of rutin on liver enzymes in PFOA-treated rats

Groups	AST(U/L)	ALT(U/L)
Control	145±9.2	60.3±3.5
R(100 mg/kg)	144±4.8	61.6±1.7
PFOA(10 mg/kg)	198.1±9.37 <sup>###</sup>	79.3±5.9 <sup>###</sup>
PFOA+R (25 mg/kg)	193±8.5 <sup>##</sup>	79±3.52 <sup>##</sup>
PFOA+R (50 mg/kg)	181.6±3.25 <sup>###</sup>	72±3.03 <sup>###</sup>
PFOA+R (100 mg/kg)	168±8.21 <sup>***,###</sup>	68.8±3.37 <sup>***,##</sup>
PFOA+Vit-C	178.1±9.37 <sup>**</sup>	71.3±3.83 <sup>###</sup>

Data are expressed as Mean±SD for six rats in each group and analyzed by ANOVA followed by Tukey's test. <sup>##</sup> $P$ <0.01 and <sup>###</sup> $P$ <0.001, in comparison with control group. <sup>\*</sup> $P$ <0.05, <sup>\*\*</sup> $P$ <0.01, and <sup>\*\*\*</sup> $P$ <0.001, in comparison with PFOA (10 mg/kg) group. PFOA: perfluorooctanoic acid; R: Rutin

## Results

### Serum biochemical evaluation.

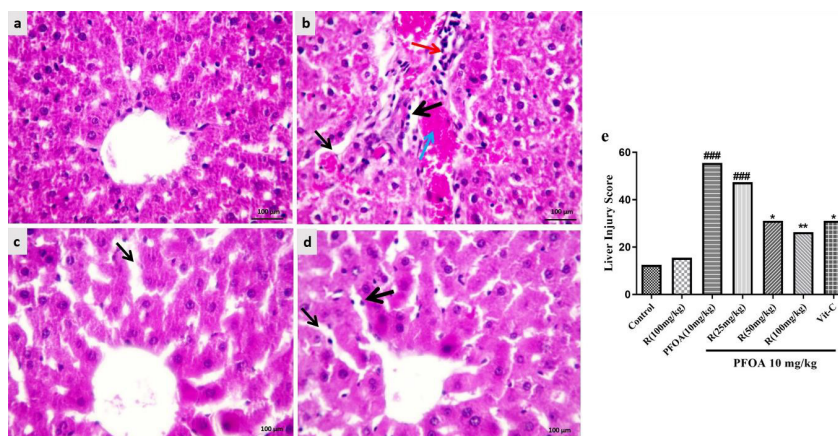
As summarized in Table 1, the PFOA group showed a marked increase in liver enzymes ( $P$ <0.001). In fact, AST and ALT increased by 33 and 19 units, respectively, in rats treated with PFOA compared to the control group. Rutin supplementation alone caused no significant change in liver enzymes. However, animals co-treated with PFOA and 50 or 100 mg/kg of rutin, or PFOA and vitamin C demonstrated significantly lower levels of these enzymes, in comparison with the PFOA group.

### Histopathological observations

Normal liver architecture was observed in the control group. However, extensive morphological changes including Kupffer cell proliferation, infiltration of the inflammatory cell, hemorrhage, and dilation of sinusoids were observed in the PFOA-treated group. Co-treatment with rutin alleviated the pathological changes induced by PFOA. Liver injury's mean grading scores are presented in Figure 1e. Liver injury score was elevated in PFOA-treated rats, which was lower in the rutin plus PFOA group compared to the PFOA group (Figure 1).

### Oxidative stress in liver tissue

Exposure to PFOA showed a significant increase in ROS



**Figure 1.** Photomicrographs show the effect of R (Rutin) on the histological architecture of the liver in PFOA (perfluorooctanoic acid) treated rats (a) control; (b) PFOA; (c) PFOA+R 50 mg/kg; (d) PFOA+R 100 mg/kg; and (e) Liver injury scores. Thick black arrow: Kupffer cell proliferation; Red arrow: Infiltration of inflammatory cell; Blue arrow: hemorrhagic; and thin black arrow: Dilation of sinusoids. Treatment with rutin ameliorated these changes. H&E staining; Mag: ×40; Scale bar = 100  $\mu\text{m}$ . The highest score belongs to the PFOA group. Rutin was able to reduce liver injury scores in the PFOA+R group

<sup>###</sup> Significantly different in comparison with the control group. <sup>\*</sup> $P$ <0.05 and <sup>\*\*</sup> $P$ <0.01 significantly different from PFOA groups

**Table 2.** Effect of rutin on biomarkers of oxidative stress and NO level in PFOA-treated rats

Groups	ROS formation (fluorescence intensity)	LPO ( $\mu\text{mol}/\text{mg}$ proteins)	GSH ( $\mu\text{mol}/\text{mg}$ proteins)	PrC ( $\text{mmol}/\text{mg}$ proteins)	SOD activity (U/ mg proteins)	NO ( $\text{nmol}/\text{ml}$ )
Control	49.9 $\pm$ 5.46	11.9 $\pm$ 0.78	207 $\pm$ 11.5	0.39 $\pm$ 0.03	11.1 $\pm$ 1.14	34.6 $\pm$ 3.08
R(100 mg/kg)	48.6 $\pm$ 8.67	11.4 $\pm$ 0.71	203 $\pm$ 9.88	0.37 $\pm$ 0.05	11.7 $\pm$ 0.38	33.4 $\pm$ 1.46
PFOA (10 mg/kg)	92.5 $\pm$ 7.61 <sup>###</sup>	18.8 $\pm$ 0.78 <sup>###</sup>	178 $\pm$ 9.11 <sup>###</sup>	0.59 $\pm$ 0.03 <sup>###</sup>	7.78 $\pm$ 0.33 <sup>###</sup>	71.4 $\pm$ 4.77 <sup>###</sup>
PFOA+R(25 mg/kg)	85.6 $\pm$ 4.24 <sup>###</sup>	18.2 $\pm$ 0.26 <sup>##</sup>	196 $\pm$ 8	0.54 $\pm$ 0.02 <sup>###</sup>	7.99 $\pm$ 0.71 <sup>###</sup>	65.7 $\pm$ 2.27 <sup>###</sup>
PFOA+R(50 mg/kg)	65.6 $\pm$ 7.80 <sup>###,*</sup>	17 $\pm$ 0.85 <sup>###,*</sup>	201 $\pm$ 8.54 <sup>*</sup>	0.51 $\pm$ 0.04 <sup>###,*</sup>	8.96 $\pm$ 0.3 <sup>###,*</sup>	62 $\pm$ 3.62 <sup>###,*</sup>
PFOA+R(100 mg/kg)	57.9 $\pm$ 5.57 <sup>###</sup>	13.6 $\pm$ 0.73 <sup>###,*</sup>	205 $\pm$ 12.9 <sup>###</sup>	0.49 $\pm$ 0.05 <sup>###,*</sup>	9.3 $\pm$ 0.26 <sup>###,*</sup>	56.9 $\pm$ 4.83 <sup>###,*</sup>
PFOA+Vit-C	80.1 $\pm$ 5.45 <sup>###</sup>	17 $\pm$ 0.81 <sup>###,*</sup>	199 $\pm$ 9.42 <sup>*</sup>	0.56 $\pm$ 0.03 <sup>###</sup>	8.93 $\pm$ 0.57 <sup>###,*</sup>	63.7 $\pm$ 3.92 <sup>###,*</sup>

Data are expressed as Mean $\pm$ SD for six rats in each group and analyzed by ANOVA followed by Tukey's test. <sup>##</sup> $P < 0.01$  and <sup>###</sup> $P < 0.001$ , in comparison with the control group. <sup>\*</sup> $P < 0.05$ , <sup>\*\*</sup> $P < 0.01$ , and <sup>\*\*\*</sup> $P < 0.001$ , in comparison with PFOA (10 mg/kg) group. PFOA: perfluorooctanoic acid; R: Rutin; ROS: reactive oxygen species; LPO: Lipid peroxidation; GSH: Reduced glutathione reduction; PrC: Protein carbonyl; SOD: Superoxide dismutase activity; NO: Nitric oxide

formation, MDA, protein carbonyl levels, and nitric oxide concentration, while GSH content and SOD activity were decreased in comparison with the control group ( $P < 0.001$ ), as shown in Table 2. Co-treatment with rutin at 50 and 100 mg/kg showed a significant decrease in ROS formation, MDA, protein carbonyl levels, and nitric oxide concentration compared to the PFOA group. Rutin at 50 ( $P < 0.01$ ) and 100 ( $P < 0.001$ ) mg/kg reversed the effects of PFOA on GSH content. Co-treatment with 50 ( $P < 0.05$ ) and 100 ( $P < 0.01$ ) mg/kg of rutin showed a significant increase in SOD activity by 1.1 and 1.5 U/ml, respectively, compared to the PFOA group. Also, vitamin C alters all mentioned factors except PrC levels. Treatment with rutin alone had no effect on the above parameters compared with the control group.

### Mitochondrial function assay

#### Mitochondrial viability

PFOA decreased mitochondrial viability in the liver by 66% compared to the control. Co-treatment with 50 ( $P < 0.01$ ) and 100 ( $P < 0.001$ ) mg/kg of rutin or vitamin C ( $P < 0.05$ ) significantly attenuated PFOA-induced mitochondrial dysfunction. The treatment with rutin alone had no effect on mitochondrial viability compared with the control group (Figure 2a).

#### Mitochondrial membrane potential

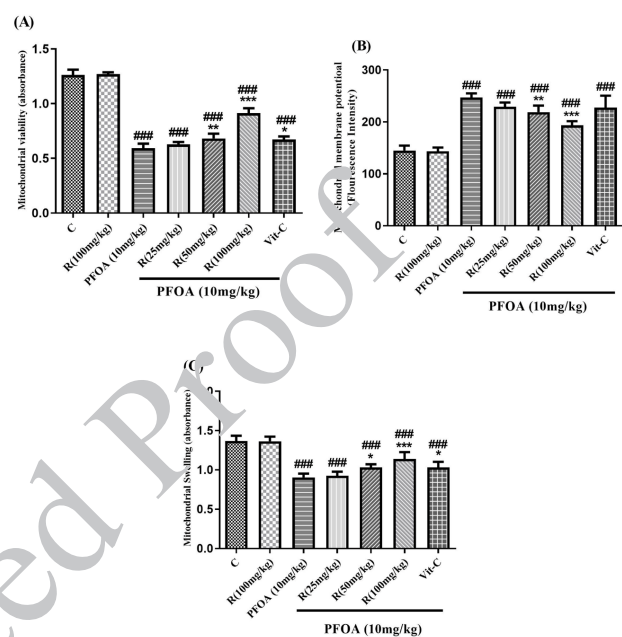
An increase in rhodamine fluorescence (MMP collapse) was more than doubled in PFOA treated animals in comparison with the control group. Besides, co-treatment with 50 ( $P < 0.01$ ) or 100 mg/kg ( $P < 0.001$ ) of rutin but not vitamin C significantly reversed the PFOA-induced MMP collapse (Figure 2b).

#### Mitochondrial swelling

As shown in Figure 2c, exposure to PFOA resulted in a significant increase in mitochondrial swelling by 46% in comparison with the control group. However, administration of rutin at doses of 50 ( $P < 0.05$ ) or 100 ( $P < 0.01$ ) mg/kg as well as vitamin C ( $P < 0.05$ ) significantly decreased mitochondrial swelling caused by PFOA.

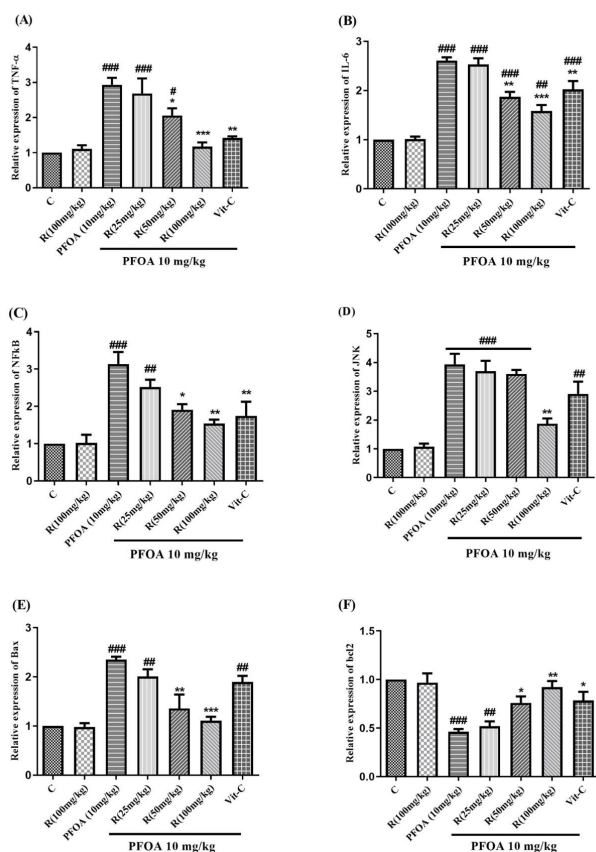
### TNF- $\alpha$ , IL-6, NF- $\kappa$ B, JNK, Bax, and Bcl-2 genes expression

According to the RT-PCR analysis, the gene expression of



**Figure 2.** Effect of rutin on (a) mitochondrial function, (b) mitochondrial membrane potential, and (c) mitochondrial swelling in PFOA-treated rats. Data are expressed as mean $\pm$ SD. <sup>###</sup> $P < 0.001$ , significantly different in comparison with the control group. <sup>\*</sup> $P < 0.05$ , <sup>\*\*</sup> $P < 0.01$ , and <sup>\*\*\*</sup> $P < 0.001$ , significantly different in comparison with PFOA (10 mg/kg) group. PFOA: perfluorooctanoic acid; R: Rutin

TNF- $\alpha$ , IL-6, NF- $\kappa$ B, and JNK increased by 1.9, 1.6, 2.1, and 2.9 times, respectively, in rats treated with PFOA compared to the control group. Co-treatment with 50 or 100 mg/kg of rutin as well as vitamin C ( $P < 0.05$ ) attenuated PFOA-induced increase of TNF- $\alpha$ , IL-6, NF- $\kappa$ B gene expressions. However, only high-dose rutin was capable of mitigating the PFOA-induced JNK expression. Rats exposed to rutin alone did not show a significant difference in the expression of TNF- $\alpha$ , IL-6, NF- $\kappa$ B, and JNK, compared with the control group (Figure 3). According to the RT-PCR analysis, the gene expression of Bax was more than doubled, and the gene expression of Bcl-2 was almost halved in animals treated with PFOA ( $P < 0.001$ ), compared to the control. Co-treatment with rutin at 50 or 100 mg/kg decreased the PFOA-induced increase of the Bax: Bcl-2 ratio. However, rutin treatment did not affect the Bax: Bcl-2 ratio, per se (Figure 3).



**Figure 3.** Effect of treatments on (a) TNF- $\alpha$ , (b) IL-6, (c) NF- $\kappa$ B, (d) JNK, (e) Bax, and (f) Bcl-2 gene expression in rat liver tissue. GAPDH served as an internal standard. Data are expressed as mean $\pm$ SD. \* $P$ <0.05, \*\* $P$ <0.01, and \*\*\* $P$ <0.001, in comparison with the control group. \* $P$ <0.05, \*\* $P$ <0.01, and \*\*\* $P$ <0.001 were significantly different in comparison with PFOA (10 mg/kg) group. PFOA: perfluorooctanoic acid; R: Rutin

## Discussion

PFOA is a durable chemical commonly used in numerous applications in industrial processes. Recently, there has been increasing global concern about the environmental and health risks of PFOA. It has been shown that exposure to PFOA is associated with an array of human diseases, including hepatic injury which is marked by liver enlargement and fatty liver (3).

Liver damage was proved by significant rise in ALT and AST levels in rats treated with PFOA, which is consistent with previous reports (1). Histopathological examination of liver sections in PFOA-treated rats also revealed various morphological changes. As shown in the results, the increase in liver enzymes (Table 1) and morphological defects (Figure 1) were significantly less in rats co-treated with PFOA and rutin or PFOA and vitamin C compared to those receiving only PFOA, although they were still higher than in the control group. These findings suggest that the administration of rutin or vitamin C alongside PFOA may confer some protective effect against PFOA-induced liver damage.

The Role of oxidative stress in PFOA-induced hepatotoxicity was exhibited by enhanced ROS production, increased lipid peroxidation, reduced GSH content, and decreased activity of the antioxidant enzymes such as SOD or CAT (35, 36). The research also revealed that excessive

ROS formation and elevated levels of MDA and Pr.C, which are end-products of lipid and protein oxidation respectively, were present in the PFOA group. Additionally, the study found that the GSH content and SOD activity, which are crucial components of the body's defense mechanism against oxidative damage, were significantly reduced in response to PFOA exposure, as shown in Table 2 (37, 38). PFOA-mediated increased ROS production is associated with impaired oxidative phosphorylation. On the other hand, PFOA-induced oxidation of the thiol groups in mitochondrial permeability transition (MPT) pores interfere with mitochondrial membrane potential and result in the release of matrix calcium, and osmotic mitochondrial swelling. These events ultimately lead to cytochrome c release from mitochondria, which initiates the internal apoptotic pathway (6, 39). Our study revealed that the PFOA treatment group showed lower mitochondrial viability, higher mitochondrial membrane potential collapse, and osmotic swelling when compared to the control group (Figure 2). Furthermore, the PFOA treatment group demonstrated a significant increase in Bax expression and a decrease in Bcl-2 expression (Figure 3).

NF- $\kappa$ B, a transcription factor, is a key player in regulating the expression of numerous genes that participate in inflammatory responses. This pathway is triggered by diverse stimuli, such as pathogens, environmental changes, and oxidative processes (40). Furthermore, oxidants are capable of inducing the phosphorylation of JNK, which belongs to the mitogen-activated protein kinases family and is also known as stress-activated protein kinase (41-43). The phosphorylation of c-Jun by JNK can trigger an inflammatory response, leading to the formation of active AP-1 transcription factors that transcribe genes responsible for inflammation and apoptosis, such as TNF- $\alpha$  (42). PFOA has been found to activate NF- $\kappa$ B and downstream pro-inflammatory cytokines, resulting in mast cell-mediated allergic inflammation. (44). The study found that rats administered PFOA exhibited increased expression levels of NF- $\kappa$ B, TNF- $\alpha$ , IL-6, and JNK (Figure 3). However, the administration of rutin and vitamin C supplements effectively inhibited the pro-inflammatory effects of PFOA (Figure 3). Rutin was also observed to alleviate liver damage induced by CCl<sub>4</sub> by inhibiting the NF- $\kappa$ B, TNF- $\alpha$ , and cyclooxygenase-2 (COX-2) pathways (45). Additionally, rutin was found to have anti-inflammatory properties against COX-2 expression induced by ultraviolet B through modulation of MAPK signaling (16).

Rutin as well as vitamin C has the ability to improve the harmful effects of PFOA on the liver tissue, including oxidative stress, apoptosis, and inflammation. However, the reversal was not entirely complete in some factors at the studied doses. In fact, rutin shows the capability to complete/almost complete reversal of PFOA effects on ROS formation, GSH content, JNK, Bax: Bcl2 ratio, NF- $\kappa$ B, and the expression of TNF- $\alpha$ . This was evident by these variables returning to their normal levels. In contrast, LPO, SOD activity, protein carbonylation, NO content, mitochondrial dysfunction, mitochondrial pore collapse, mitochondrial swelling, and IL-6 gene expression remained elevated in rats that were exposed to both rutin and PFOA compared to the normal group. Albeit, they were significantly lower than the corresponding levels in rats treated only with PFOA. This suggests that rutin partially restored the damaging

effects of PFOA on liver function, which may account for the persistence of abnormality in the liver enzyme function (Table 1) or morphology (Figure 1). In this regard, rutin could protect against CCL<sub>4</sub>-induced hepatotoxicity via complete inhibition of CCL<sub>4</sub>-mediated overexpression of NF-κB and TNF-α (45, 46).

This study suggests that at a dose of 100 mg/kg/day rutin was effective or more effective than vitamin C at reversing the disturbances caused by PFOA. Notably, vitamin C did not have any significant preventive effects on protein carbonylation, mitochondrial membrane potential, and JNK expression. On the other hand, rutin was able to partially alleviate the negative impact of PFOA on these variables.

Further research is required to fully understand the extent of the protection provided, however, it appears that rutin may be more effective than vitamin C in mitigating PFOA-induced hepatotoxicity. This suggests that rutin has superior protective properties compared to vitamin C.

## Conclusion

Based on our present study, rutin could ameliorate PFOA-induced liver injury via partial restoration of oxidative damage and mitochondrial dysfunction as well as suppression of pro-inflammatory or pro-apoptotic gene expression. These findings may be useful for future application of rutin in the prevention and treatment of hepatotoxicity caused by environmental toxins.

## Acknowledgment

This work was funded by the Research Deputy of Mazandaran University of Medical Sciences, Sari, Iran (grant number: 6354). The data presented here are parts of Maloos Naderi's PhD thesis.

## Authors' Contributions

M N, M S, F T, and F S H designed the experiments; M N performed experiments and collected data; M N, M S, F S H, and S H A discussed the results and strategy; F S H supervised, directed, and managed the study; M N, M S, F T, S H A, and F S H approved the final version to be published.

## Conflicts of Interest

The authors declare that they have no conflicts of interest.

## References

- Li D, Zhang L, Zhang Y, Guan S, Gong X, Wang X. Maternal exposure to perfluorooctanoic acid (PFOA) causes liver toxicity through PPAR-α pathway and lowered histone acetylation in female offspring mice. *Environ Sci Pollut Res Int* 2019; 26:18866-18875.
- Yang G, Zhang N, Yang J, Fu Q, Wang Y, Wang D, et al. Interaction between perfluorooctanoic acid and aerobic granular sludge. *Water Res* 2020; 169:115249-115259.
- Yang B, Zou W, Hu Z, Liu F, Zhou L, Yang S, et al. Involvement of oxidative stress and inflammation in liver injury caused by perfluorooctanoic acid exposure in mice. *Biomed Res Int* 2014; 2014:409837-409843.
- Erdemli M, Yigitcan B, Gul M, Bag HG, Gul S, Aksungur Z. Thymoquinone is protective against 2, 3, 7, 8-tetrachlorodibenzo-p-dioxin induced hepatotoxicity. *Biotech Histochem* 2018; 93:453-462.
- Meyer JN, Leung MC, Rooney JP, Sandoel A, Hengartner MO, Kisby GE, et al. Mitochondria as a target of environmental toxicants. *Toxicol Sci* 2013; 134:1-17.
- Mashayekhi V, Tehrani KHME, Hashemzadeh M, Tabrizian K, Shahraki J, Hosseini M. Mechanistic approach for the toxic

effects of perfluorooctanoic acid on isolated rat liver and brain mitochondria. *Hum Exp Toxicol* 2015; 34:985-996.

- Suh KS, Choi EM, Kim YJ, Hong SM, Park SY, Rhee SY, et al. Perfluorooctanoic acid induces oxidative damage and mitochondrial dysfunction in pancreatic β-cells. *Mol Med Rep* 2017; 15:3871-3878.
- Gedik S, Erdemli ME, Gul M, Yigitcan B, Bag HG, Aksungur Z, et al. Hepatoprotective effects of crocin on biochemical and histopathological alterations following acrylamide-induced liver injury in Wistar rats. *Biomed Pharmacother* 2017; 95:764-770.
- Bilgic Y, Akbulut S, Aksungur Z, Erdemli ME, Ozhan O, Parlakpinar H, et al. Protective effect of dexpanthenol against cisplatin-induced hepatotoxicity. *Exp Ther Med* 2018; 16:4049-4057.
- Lebda MA, Sadek KM, Abouzed TK, Tohamy HG, El-Sayed YS. Melatonin mitigates thioacetamide-induced hepatic fibrosis via antioxidant activity and modulation of proinflammatory cytokines and fibrogenic genes. *Life Sci* 2018; 192:136-143.
- Brieger A, Bienefeld N, Hasan R, Goerlich R, Haase H. Impact of perfluorooctanesulfonate and perfluorooctanoic acid on human peripheral leukocytes. *Toxicol in Vitro* 2011; 25:960-968.
- Hoesel B, Schmid JA. The complexity of NF-κB signaling in inflammation and cancer. *Mol Cancer* 2013; 12:1-15.
- Sadek K, Saleh E, Nasr S. Molecular hepatoprotective effects of lipoic acid against carbon tetrachloride-induced liver fibrosis in rats: Hepatoprotection at molecular level. *Hum Exp Toxicol* 2018; 37:142-154.
- Workman LM, Habelsh H. TNFR1 signaling kinetics: spatiotemporal control of three phases of IKK activation by posttranslational modification. *Cell Signal* 2013; 25:1654-1664.
- Lan HY, Nikolic-Pavlovic DJ. Advances in mechanisms of renal fibrosis. *Front Physiol* 2018; 9:284-285.
- Kim JH, Kim BB, Lee KW, Kang NJ. Protective effect of rutin against ultraviolet B-induced cyclooxygenase-2 expression in mouse epidermal cells. *Food Sci Biotechnol* 2013; 22:1-6.
- Zhang W, Zhang D, Kang J, Meng X, Yang J, Yang L, et al. Protective effects of rutin on liver injury in type 2 diabetic db/db mice. *Biomed Pharmacother* 2018; 107:721-728.
- Zargar S, Wani TA, Alamro AA, Ganaie MA. Amelioration of thioacetamide-induced liver toxicity in Wistar rats by rutin. *Int J Immunopathol Pharmacol* 2017; 30:207-214.
- Abdel-Ghaffar O, Mahmoud ST, Said AA, Sanad FA-AY. Hepatoprotective effect of rutin against oxidative stress of isoniazid in albino rats. *Int J Pharmacol* 2017; 13:516-528.
- Guruge KS, Yeung LW, Yamanaka N, Miyazaki S, Lam PK, Giesy JP, et al. Gene expression profiles in rat liver treated with perfluorooctanoic acid (PFOA). *Toxicol Sci* 2006; 89:93-107.
- Naderi M, Seyedabadi M, Amiri FT, Mohammadi E, Akbari S, Shaki F. Taurine protects against perfluorooctanoic acid-induced hepatotoxicity via inhibition of oxidative stress, inflammatory, and apoptotic pathways. *Toxicol Res* 2023; 12:124-132.
- Hamzeh M, Hosseinimehr SJ, Khalatbary AR, Mohammadi HR, Dashti A, Amiri FT. Atorvastatin mitigates cyclophosphamide-induced hepatotoxicity via suppression of oxidative stress and apoptosis in rat model. *Res Pharm Sci* 2018; 13:440-449.
- Bradford MM. A rapid and sensitive method for the quantitation of microgram quantities of protein utilizing the principle of protein-dye binding. *Anal Biochem* 1976; 72:248-254.
- Arab-Nozari M, Mohammadi E, Shokrzadeh M, Ahangar N, Amiri FT, Shaki F. Co-exposure to non-toxic levels of cadmium and fluoride induces hepatotoxicity in rats via triggering mitochondrial oxidative damage, apoptosis, and NF-κB pathways. *Environ Sci Pollut Res Int* 2020; 27:24048-24058.
- Owagboriaye E, Dedede G, Aladesida A, Bamidele J, Olooto W. Assessment of the effect of gasoline fume on stress hormones, anti-oxidant status and lipid peroxidation in albino rat. *J King Saud Univ Sci* 2018; 30:393-399.
- Akbari S, Amiri FT, Naderi M, Shaki F, Seyedabadi M. Sodium arsenite accelerates D-galactose-induced aging in the testis of the rat: Evidence for mitochondrial oxidative damage, NF-κB, JNK,

- and apoptosis pathways. *Toxicology* 2022; 470:153148.
27. Ashari S, Karami M, Shokrzadeh M, Ghandadi M, Ghassemi-Barghi N, Dashti A, *et al.* The implication of mitochondrial dysfunction and mitochondrial oxidative damage in di (2-ethylhexyl) phthalate induced nephrotoxicity in both *in vivo* and *in vitro* models. *Toxicol Mech Methods* 2020; 30:427-437.
28. Seyedabadi M, Ghahremani MH, Ostad SN. ATP depletion as a consequence of hypoxia enhances tamoxifen antiproliferative effects in T47D breast carcinoma cells. *Oncol Res* 2009;18:221-228.
29. Baracca A, Sgarbi G, Solaini G, Lenaz GJBeba-b. Rhodamine 123 as a probe of mitochondrial membrane potential: Evaluation of proton flux through F0 during ATP synthesis. *Biochim Biophys Acta* 2003; 1606:137-146.
30. Mohammadnejad L, Soltaninejad K, Seyedabadi M, Ghasem Pouri SK, Shokrzadeh M, Mohammadi H. Evaluation of mitochondrial dysfunction due to oxidative stress in therapeutic, toxic and lethal concentrations of tramadol. *Toxicol Res* 2021; 10:1162-1170.
31. Khedmat S, Seyedabadi M, Ghahremani MH, Ostad SN. Cyclooxygenase 2 plays a role in Emdogain-induced proliferation. *J Periodontal Res* 2011; 46:67-73.
32. Mandegary A, Torshabi M, Seyedabadi M, Amirheidari B, Sharif E, Ghahremani MH. Indomethacin-enhanced anticancer effect of arsenic trioxide in A549 cell line: Involvement of apoptosis and phospho-ERK and p38 MAPK pathways. *Biomed Res Int* 2013; 2013:237543-237551.
33. Najafi A, Moradinasab M, Seyedabadi M, Haghighi MA, Nabipour I. First molecular identification of symbiotic archaea in a sponge collected from the Persian Gulf, Iran. *Open Microbiol J* 2018; 12:323-332.
34. Quist EM, Filgo AJ, Cummings CA, Kissling GE, Hoenerhoff MJ, Fenton SE. Hepatic mitochondrial alteration in CD-1 mice associated with prenatal exposures to low doses of perfluorooctanoic acid (PFOA). *Toxicol Pathol* 2015; 43:546-557.
35. Ojo AF, Xia Q, Peng C, Ng JC. Evaluation of the individual and combined toxicity of perfluoroalkyl substances to human liver cells using biomarkers of oxidative stress. *Chemosphere* 2021; 281:130808.
36. Liu W, Xu C, Sun X, Kuang H, Kuang X, Zou W, *et al.* Grape seed proanthocyanidin extract protects against perfluorooctanoic acid-induced hepatotoxicity by attenuating inflammatory response, oxidative stress and apoptosis in mice. *Toxicol Res* 2016; 5:224-234.
37. Galano A, Alvarez-Idaboy JR. Glutathione: Mechanism and kinetics of its non-enzymatic defense action against free radicals. *Rsc Advances* 2011; 1:1763-1771.
38. Zeweil MM, Sadek KM, Elsayed MF, Mahmoud SF, Ahmed BM, Khafaga AF. Sidr honey abrogates the oxidative stress and downregulates the hyaluronic acid concentration and gene expression of TGF- $\beta$ 1 and COL1a1 in rat model of thioacetamide-induced hepatic fibrosis. *Anim Sci J* 2020; 91:e13434.
39. Huang Q, Zhang J, Martin FL, Peng S, Tian M, Mu X, *et al.* Perfluorooctanoic acid induces apoptosis through the p53-dependent mitochondrial pathway in human hepatic cells: A proteomic study. *Toxicol Lett* 2013; 223:211-220.
40. Oeckinghaus A, Ghosh S. The NF- $\kappa$ B family of transcription factors and its regulation. *Cold Spring Harbor Perspect Biol* 2009; 1:a000034-000047.
41. Roy PK, Rashid F, Bragg J, Ibdah JA. Role of the JNK signal transduction pathway in inflammatory bowel disease. *World J Gastroenterol* 2008; 14:200-202.
42. Grynberg K, Ma FY, Nikolic-Paterson DJ. The JNK signaling pathway in renal fibrosis. *Front Physiol* 2017; 8:829-840.
43. Sadek KM, Lebda MA, Abouzeid TK, Nasr SM, El-Sayed Y. The molecular and biochemical insight view of lycopene in ameliorating tramadol induced liver toxicity in a rat model: Implication of oxidative stress, apoptosis, and MAPK signaling pathways. *Environ Sci Pollut Res Int* 2018; 25:33119-33130.
44. Singh TS, Lee S, Kim H-H, Choi JK, Kim S-H. Perfluorooctanoic acid induces mast cell-mediated allergic inflammation by the release of histamine and inflammatory mediators. *Toxicol Lett* 2012; 216:64-70.
45. Domitrović R, Jakovac H, Vasiljev Marchesi V, Vladimirović S, Cvijanović O, Tadić Ž, *et al.* Differential hepatoprotective mechanisms of rutin and quercetin in CCl<sub>4</sub>-intoxicated BALB/cN mice. *Acta Pharmacologica Sinica* 2012; 33:1260-1270.
46. AlSharari SD, Al-Rejaie SS, Abuhashish HM, Ahmed MM, Hafez MM. Rutin attenuates Hepatotoxicity in high-cholesterol-diet-fed rats. *Oxid Med Cell Longev* 2016;2016:5436745-54367455.