

The protective activity of noscapine on renal ischemia-reperfusion injury in male Wistar rat

Mehrangiz Khanmoradi ¹, Seyyed Ali Mard ², Nahid Aboutaleb ^{1*}, Malihe Nobakht ³, Masoud Mahmoudian ⁴

¹ Physiology Research Center and Physiology Department, Faculty of Medicine, Iran University of Medical Sciences, Tehran, Iran

² Physiology Research Center (PRC), Research Institute for Infectious Diseases of Digestive System and Department of Physiology, School of Medicine, Jundishapur University of Medical Sciences, Ahvaz, Iran

³ Department of Anatomy, School of Medicine, Iran University of Medical Sciences, Tehran, Iran

⁴ Department of Pharmacology, School of Medicine, Iran University of Medical Sciences, Tehran, Iran

ARTICLE INFO

Article type:
Original article

Article history:
Received: Aug 1, 2013
Accepted: Dec 11, 2013

Keywords:
BUN
Creatinine
Noscapine
Rat
Renal ischemia-reperfusion injury

ABSTRACT

Objective(s): Bradykinin is a part of the kinin-kallikrein system which is involved in ischemia-reperfusion injury via B₁ and B₂ receptors. Noscapine is a non-competitive antagonist of bradykinin receptors. Noscapine has been reported to be able to protect some organs against ischemia-reperfusion injury but its effect on renal ischemia-reperfusion injury (RIR) in rats is unknown. Therefore, the present study was designed to evaluate the effect of noscapine on renal ischemia-reperfusion injury in rats.

Materials and Methods: Twenty four rats were randomly assigned to four groups; sham, RIR control, pre-and post-treatment with noscapine. To induce RIR injury, 20 days after right nephrectomy, animals underwent a midline laparotomy and the renal artery was clamped for 40 min to induce ischemia, and the clamp was then removed to allow reperfusion for 48 hr. Animals received noscapine or vehicle 1 hr before RIR or just prior to reperfusion. At the end of the experiment, animals were killed by cardiac exsanguination. Blood samples were collected to assess blood urea nitrogen (BUN) and creatinine. The kidneys were also removed for histopathological and western-blot analysis.

Results: Noscapine treatment 1 hr before RIR or just prior to reperfusion protects the renal tissue structure as compared with the control. The expression levels of the studied inflammatory mediators, TNF- α and MCP-1in pretreated-, and treated-noscapine groups decreased as compared with the control group. The levels of BUN and creatinine in pre-, and post-treated noscapine groups were significantly lower than in control animals.

Conclusion: Noscapine protects renal tissue structure and function against RIR through down-regulation of the inflammatory mediators.

► Please cite this paper as:

Khanmoradi M, Mard SA, Abotaleb N, Nobakht M, Mahmoudian M. The protective activity of noscapine on renal ischemia-reperfusion injury in male Wistar rat. Iran J Basic Med Sci 2014; 17:244-249.

Introduction

One of the most common reasons for renal ischemia-reperfusion (RIR) is renal transplantation (1). It has been shown that ischemia-reperfusion (I/R) injury affects a variety of renal cells such as tubular epithelial cells and endothelial cells. Following the activation of the inflammatory reactions during I/R injury, tumor necrosis factor- α (TNF- α) and interleukin 1 β (IL-1 β) are released (2). There are many reports about the effect of the activation of bradykinin receptor (B₁ and B₂) on I/R injuries in different organs. Many reports have shown that bradykinin plays a deleterious effect in the lung (3), liver (4) and intestine (5, 6) after I/R injury. Additionally, early activation of B₂ receptor has been shown to increase the production of

reactive oxygen species and disturb renal function following RIR in rats (7).

Noscapine is an iso-quinolinin alkaloid and a non-competitive bradykinin receptors antagonist which has been shown to reduce cerebral edema after brain hypoxic ischemia (8). The effect of noscapine on RIR is unknown. Therefore, the present study was designed to evaluate the effect of noscapine on RIR injury in male Wistar rats.

Materials and Methods

Animals

Male Wistar rats (body weight: 220-280 g) were purchased from the animal house of Institute Pasteur, Tehran, Iran. The animals were fed on

*Corresponding author: Nahid Abotaleb, Physiology Research Center, Department of Physiology, School of Medicine, Iran University of Medical Sciences, Tehran, Iran. Tel: +98-21-82944549; email: dr_nabo40@yahoo.com

Figure 1A

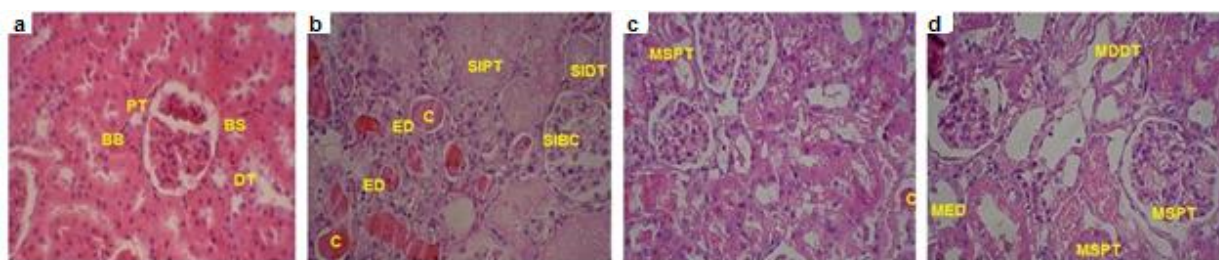


Figure 1B

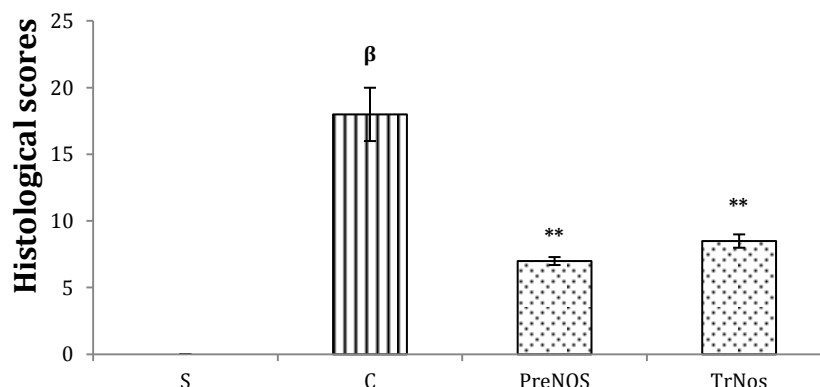


Figure 1. Histologic changes after RIR. Administration of noscapine protects the renal tissue structure against renal I/R injury in rats. a: Sham-operated group shows normal tissue. b: I/R Control group; c: Rats received noscapine (2 mg/kg,IP) one hour before RIR and d: Rats received noscapine (2 mg/kg,IP) just prior to reperfusion. PT: proximal tubule; DT: distal tubule; BS: Bowman space; BB: Brush border; BC: Bowman capsule; L: lumen; SIPT: severe inflammation of proximal tubule; SIDT: severe inflammation of distal tubule; SIBC: severe inflammation of Bowman capsule; ED: Epithelial disruption; C: Cast; MSPT: mild swelling of proximal tubule; MDDT: mild dilatation of distal tubule; MSPT: mild swelling of proximal tubule; MSBC: mild swelling of Bowman capsule; MED: mild epithelial disruption. All of the sections were stained with hematoxylin and eosin; (1-4) $\times 400$ magnification. Asterisk indicates a significant decrease ($*P < 0.01$) as compared to the control group. β indicates a significant increase ($^{\beta}P < 0.001$) as compared to sham-operated group. Data are expressed as mean \pm SEM

conventional diets and had free access to water. They were maintained under standard conditions of humidity, temperature ($22 \pm 2^{\circ}\text{C}$) and light/dark cycle (12 hr: 12 hr). All experiments were carried out in accordance with the ethics committee of Iran University of Medical Sciences, Tehran, Iran.

Induction of renal ischemia-reperfusion injury

Animal in all experimental groups were anesthetized using intraperitoneally administered pentobarbital (50 $\mu\text{g}/\text{kg}$) and then underwent right nephrectomy. To induce RIR injury, 20 days after right nephrectomy, animals underwent a midline laparotomy, and the renal pedicle was carefully isolated. Then, the renal artery was clamped for 40 min using an arterial clamp to induce ischemia, and the clamp was then removed to allow reperfusion for 48 hr. Sham-operated rats underwent laparotomy without inducing RIR injury. In all groups, the abdominal incision was double-sutured immediately after beginning reperfusion (7).

Animal grouping and treatment

Twenty four male Wistar rats were randomly assigned to 4 groups; sham, RIR control, pre-and post-treatment with noscapine. Sham-operated and

RIR control rats received saline (0.5 ml, IP); pre-treated noscapine animals received noscapine 2 mg/kg (IP) 1 hr before RIR and post-treated animals received noscapine 2 mg/kg (IP) just prior to reperfusion. Forty hours after RIR, animals were killed by cardiac exsanguination. To assess the renal function, blood samples were collected in chilled tubes and were centrifuged at 3500 rpm for 10 min. Serum samples were kept at -20°C until the measurement of creatinine. Pars Azmoon (Iran) kits were used to measure the serum level of creatinine and blood urea nitrogen (BUN). One part of the explanted kidney was immediately snap frozen in liquid nitrogen and stored at -80°C until protein analysis and the other part was fixed in 10% formalin for histologic evaluation.

Histological evaluation

For histological evaluation, as mentioned earlier, the explanted kidneys from all studied groups were fixed in 10% formalin, kept for 3 weeks, dehydrated in graded ethanol, and embedded in paraffin. Thereafter, sections of tissue were cut at 4 μm using a microtome, stained with hematoxylin and eosin. Tubular damage was scored using a scoring system ranging 0-3 by an observer who was unaware of the

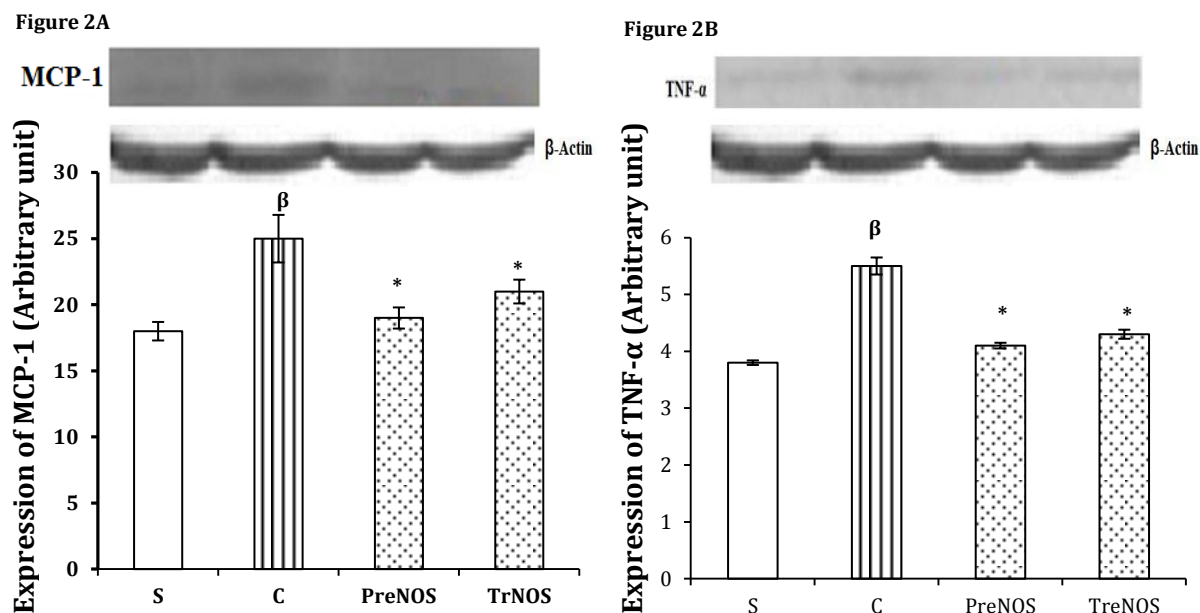


Figure 2. Effect of noscapine administration on expression of TNF- α and MCP-1 in RIR in rats. Administration of noscapine just prior to reperfusion and also 1 h before RIR, decreased the expression of MCP-1 (A) and TNF- α (B). For description of the experimental groups, see caption to Figure 1. Asterisk indicates a significant decrease ($*P<0.01$) as compared to the control group. β indicates a significant increase ($\beta P<0.01$) as compared to sham-operated group. Data are expressed as mean \pm SEM

study. The score was as follows: normal=0; mild=1; moderate=2 and severe=3. The following variables were assessed: casts formation, tubular dilation swelling, diffuse interstitial edema, epithelial detachment, expansion of Bowman's capsule, loss of nuclei and loss of brush border (9).

Protein extraction and western blot analysis

The frozen kidney tissue was homogenized in homogenization buffer containing protease inhibitors and protein extracted using TriPure isolation reagent (Roche Diagnostics, Germany). The concentration of the extracted proteins was determined using Bradford method and the protein expression was evaluated by western blotting as previously described (10). The protein pellets were mixed with SDS-buffer, boiled for 5 min and then centrifuged at 15000 rpm for 5 min at 4°C. The extracted proteins were separated using SDS-PAGE on 12% acrylamide gels and transferred to a PVDF membrane. The membranes were blocked with 5% non-fat dry milk dissolved in tris-buffered saline with 0.1% tween 20 (TBST, pH 7.6) for 3 hr and then incubated overnight at 4°C with anti-MCP-1; monocyte chemoattractant protein-1[ab7202] (dilution 1:1000; Abcam, USA), anti-TNF- α antibody (ab66579) (dilution 1:1000; Abcam, USA), or anti- β -actin antibody [ab20272] (dilution 1:5000; Abcam, USA). After three times washing with TBST, the secondary antibody was applied for 1 hr at room temperature. Goat Anti-Rabbit IgG H&L (HRP) (ab6721, USA) was used as the secondary antibody for TNF- α , MCP-1 and β -actin. Band intensity was measured densitometrically using UV.doc

software (Bio-Rad, USA) and the values were normalized to β -actin.

Statistical analysis

Data are shown as mean \pm SEM. Statistical analysis was performed by one-way ANOVA and followed by post hoc Tukey's test. Significance was set at a $P<0.05$ level.

Results

Noscapine protects the renal tissue after RIR

Forty min renal ischemia followed by 48 hr reperfusion significantly increased cast formation, tubular dilation swelling, diffuse interstitial edema, epithelial detachment and expansion of Bowman's capsule as compared with the sham-operated rats (Figure 1 A-B; $P<0.001$). As shown in Figures 1C and D, administration of noscapine just prior to reperfusion and also one hour before RIR protects the renal tissue structure. Cast formation, tubular dilation swelling, diffuse interstitial edema, epithelial detachment and expansion of Bowman's capsule in noscapine-treated and pretreated animals were significantly lower than those of control group ($P<0.01$).

Administration of noscapine decreased the level of inflammatory mediators on RIR in rats

According to Figure 2 A and B, the results of western blotting analysis showed that administration of noscapine just prior to reperfusion and also 1 hr before RIR, decreased the expression of MCP-1 and TNF- α ($P<0.01$).

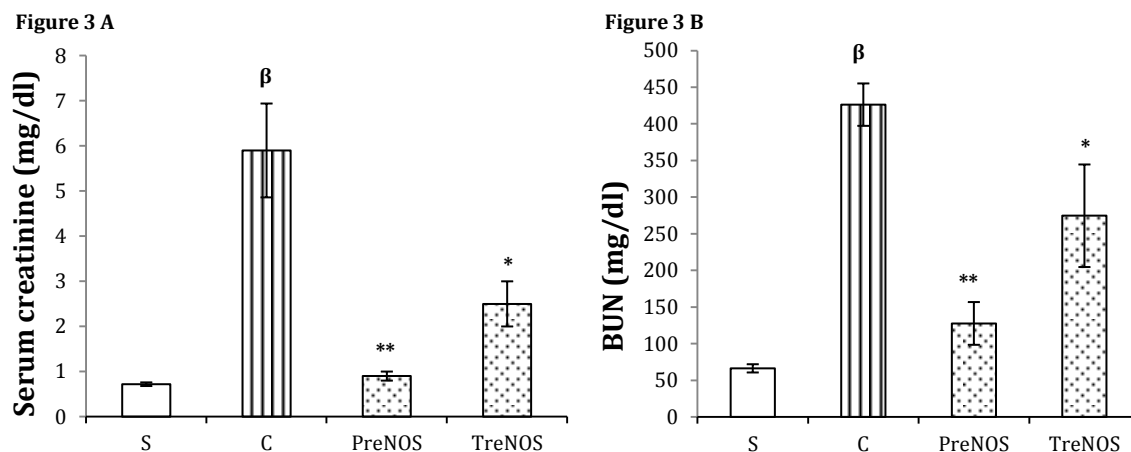


Figure 3. Effect of noscapine administration on renal function after I/R in rats. Administration of noscapine just prior to reperfusion and also 1 h before RIR decreased serum levels of creatinine (A) and also BUN levels (B) as compared to control group. For more details about the experimental groups, see the caption of Figure 1. Asterisk indicates a significant decrease (* $P < 0.05$; ** $P < 0.01$) as compared to the control group. β indicates a significant increase ($P < 0.001$) as compared to sham-operated group. Data are expressed as mean \pm SEM

Administration of noscapine improves the renal function after RIR in rats

The results showed that 48 hr after RIR, serum creatinine and BUN were significantly increased in control rats as compared with the sham-operated animals ($P < 0.001$, Figures 3A and B). Noscapine treatment improves the renal function. As shown in Figures 3A and B, serum creatinine and BUN levels were significantly decreased in noscapine-treated and pretreated rats as compared with the control rats.

Discussion

The protective effects of bradykinin receptor antagonists [FR173657 and Hoe 140] have been shown in different models of tissue injuries such as the intestine and renal ischemia/reperfusion injuries (6, 7). Noscapine, a non-competitive bradykinin receptors antagonist, has been shown to decrease brain edema and damage against hypoxic/ischemic insult in neonatal rats (8). Moreover, it has been reported that oral administration of noscapine to acute ischemic stroke patients improves clinical prognosis and decreases the mortality rates (12). Other well-known beneficial effects of noscapine are antitussive (15) and anti-tumor activity (13, 14, 16, 17). Consistent with these reports, the present study showed the protective role of noscapine against RIR injury in male Wistar rats, for the first time. On the basis of the histological analysis, inhibition of bradykinin receptors by an intraperitoneal injection of noscapine 1 hr before RIR as pretreatment and also just prior to reperfusion as treatment, protects the renal tissue structure against RIR injury in rats (Figures 1A and B).

Tumor necrosis factor- α has been shown to be secreted at early stages of ischemia-reperfusion injuries and mediate the induction of other chemokines such as monocyte chemoattractant protein1 (MCP-1) to attract leukocytes migrating to

the inflammatory site which finally results in the inflammation (18). Additionally, it has been reported that over expression of TNF- α stimulates the expression of chemokines like MCP-1 (19). Moreover, it has been reported that MCP-1 contributes to the recruitment of macrophages which is associated with glomerulosclerosis and fibrosis (20). Jiang *et al* reported that a single administration of mycophenolate mofetil, a relatively novel immunosuppressant, improved the renal function and inhibited the formation of fibrosis in I/R injury in Sprague-Dawley rats which may be due to a decrease in MCP-1 and TGF- β 1 expression as well as macrophage infiltration (21). Also, Jia *et al* showed that short hairpin RNA of endothelin A receptor, ETaR shRNA, preserve the renal function in RIR in rats. In their model, shRNA down-regulated ETaR which in turn reduces the mRNA expression of ET-1 as well as other cytokines and chemokines including MCP-1 and TNF- α subsequently improved renal function and structure (22). Moreover, Chiang and his co-workers also showed that Hoe 140, an antagonist of bradykinin receptors, protects the renal function against RIR by down-regulating the gene expression of MCP-1 and TNF- α , parallel with reducing their plasma levels (7). Consistent with these results, our findings showed that a single injection of noscapine decreased the expression of TNF- α and MCP-1 which proposes the reduction in expression of inflammatory cytokine and chemokine as a possible mechanism for the renoprotective activity of noscapine. Therefore, it can be concluded that the renoprotective effect of noscapine on I/R injury is partly mediated by down-regulation of the inflammatory protein expression.

In the present study, in order to assess the protective effect of noscapine on renal function, we measured the levels of BUN and creatinine. Forty eight hours after RIR, the levels of BUN and

creatinine in control animals were significantly higher than those in sham-operated rats which shows that the renal function was impaired by I/R injury (Figures 3A and B). According to Figures 3 A and B, the administration of noscapine just prior to reperfusion and 60 min before the onset of ischemia significantly reversed these levels. These findings suggest that noscapine effectively downregulates the expression of inflammatory mediators and subsequently improves the renal tissue structure and renal function. The findings also showed that the levels of BUN and creatinine in noscapine-pretreated rats that received it 60 min before the onset of I/R were significantly lower as compared with noscapine-treated animals. Therefore, to achieve better protective results, the time of noscapine administration is an important factor. We suggest that earlier inhibition of bradykinin receptors can be more effective. Consistent with these results, Chiang and his co-workers showed that early activation of bradykinin receptors by kallikrein had more deleterious effects in the corresponding animals on renal tissue function and structure as compared with the kallikrein-treated rats with RIR (7).

Conclusion

The present study, showed the renoprotective effect of noscapine on I/R injury, for the first time. The findings of this study demonstrated that: Pretreatment with noscapine improved the levels of BUN and creatinine and the renal function following RIR.

The protein expression of TNF- α and MCP-1 in noscapine-pretreated rats were lower as compared with control rats.

Acknowledgment

The authors are thankful to Vice Chancellor of Research of Iran University of Medical Sciences, Tehran, Iran, for financial support.

Conflict of Interests

All authors declare that they have no conflicts of interest.

References

- Halloran PF. Immunosuppressive drugs for kidney transplantation. *N Engl J Med* 2004; 351:2715-2729.
- Naka Y, Roy DK, Smerling AJ, Michler RE, Smith CR, Stern DM, Oz MC, Pinsky DJ. Inhaled nitric oxide fails to confer the pulmonary protection provided by distal stimulation of the nitric oxide pathway at the level of cyclic guanosine monophosphate. *J Thorac Cardiovasc Surg* 1995; 110:1434-1441.
- Hashimoto N, Takeyoshi I, Tsutsumi H, Sunose Y, Tokumine M, Totsuka O, *et al.* Effects of a bradykinin B(2) receptor antagonist on ischemia-reperfusion injury in a canine lung transplantation model. *J Heart Lung Transplant* 2004; 23:606-613.
- Totsuka O, Takeyoshi I, Tsutsumi H, Hashimoto N, Sunose Y, Tokumine M, *et al.* The effects of a bradykinin B2 receptor antagonist in extended liver resection with ischemia in dogs. *Hepatogastroenterology* 2004; 51:1771-1775.
- Souza DG, Pinho V, Pesquero JL, Lomez ES, Poole S, Juliano L, *et al.* Role of the bradykinin B2 receptor for the local and systemic inflammatory response that follows severe reperfusion injury. *Br J Pharmacol* 2003; 139:129-139.
- Arakawa K, Takeyoshi I, Akao Y, Totsuka O, Matsumoto K, Morishita Y. Bradykinin B2 receptor antagonist FR173657 ameliorates small bowel ischemia-reperfusion injury in dogs. *Dig Dis Sci* 2005; 50:27-36.
- Chiang WC, Chien CT, Lin WW, Lin SL, Chen YM, Lai CF, *et al.* Early activation of bradykinin B2 receptor aggravates reactive oxygen species generation and renal damage in ischemia/reperfusion injury. *Free Radic Biol Med* 2006; 41:1304-1314.
- Mahmoudian M, Siadatpour Z, Ziai SA, Mehrpour M, Benaissa F, Nobakht M., Reduction of the prenatal hypoxic-ischemic brain edema with noscapine. *Acta Physiol Hung* 2003; 90:313-318.
- Solez K, Racusen LC, Whelton A. Glomerular epithelial cell changes in early postischemic acute renal failure in rabbits and man. *Am J Pathol* 1981; 103:163-173.
- Villanueva S, Céspedes C, Vio CP. Ischemic acute renal failure induces the expression of a wide range of nephrogenic proteins. *Am J Physiol Regul Integr Comp Physiol* 2006; 290:R861-870.
- Wirth K, Hock FJ, Albus U, Linz W, Alpermann HG, Anagnostopoulos H, *et al.* Hoe 140 a new potent and long acting bradykinin-antagonist: *in vivo* studies. *Br J Pharmacol* 1991; 102:774-777.
- Mahmoudian M, Mehrpour M, Benaissa F, Siadatpour Z. A preliminary report on the application of noscapine in the treatment of stroke. *Eur J Clin Pharmacol* 2003; 59:579-581.
- Ke Y, Ye K, Grossniklaus HE, Archer DR, Joshi HC, Kapp JA. Noscapine inhibits tumor growth with little toxicity to normal tissues or inhibition of immune responses. *Cancer Immunol Immunother* 2000; 49:217-225.
- Zughaier S, Karna P, Stephens D, Aneja R. Potent anti-inflammatory activity of novel microtubule-modulating brominated noscapine analogs. *PLoS One* 2010; 11:e9165.
- Ebrahimi SA, Zareie MR, Rostami P, Mahmoudian M. Interaction of noscapine with the bradykinin mediation of the cough response. *Acta Physiol Hung* 2003; 90:147-155.
- Aneja R, Dhiman N, Idnani J, Awasthi A, Arora SK, Chandra R, *et al.* Preclinical pharmacokinetics and bioavailability of noscapine, a tubulin-binding anticancer agent. *Cancer Chemother Pharmacol* 2007; 60:831-839.
- Zhou J, Gupta K, Aggarwal S, Aneja R, Chandra R, Panda D, *et al.* Brominated derivatives of noscapine are potent microtubule-interfering agents that perturb mitosis and inhibit cell proliferation. *Mol Pharmacol* 2003; 63:799-807.
- Tomasoni S, Azzollini N, Casiraghi F, Capogrossi MC, Remuzzi G, Benigni A. CTLA4Ig gene transfer prolongs survival and induces donor-specific tolerance in a rat renal allograft. *J Am Soc Nephrol* 2000; 11:747-752.

19. Wolf G, Aberle S, Thaiss F, Nelson PJ, Krensky AM, Neilson EG, *et al*. TNF alpha induces expression of the chemoattractant cytokine RANTES in cultured mouse mesangial cells. *Kidney Int* 1993; 44:795-804.
20. Prasad P, Tiwari AK, Kumar KM, Ammini AC, Gupta A, Gupta R, *et al*. Association of TGFbeta1, TNF-alpha, CCR2 and CCR5 gene polymorphisms in type-2 diabetes and renal insufficiency among Asian Indians. *BMC Med Genet* 2007; 12:20.
21. Jiang S, Tang Q, Rong R, Tang L, Xu M, Lu J, *et al*. Mycophenolate mofetil inhibits macrophage infiltration and kidney fibrosis in long-term ischemia-reperfusion injury. *Eur J Pharmacol* 2012; 688:56-61.
22. Jia Y, Zhao Z, Xu M, Zhao T, Qiu Y, Ooi Y, *et al*. Prevention of renal ischemia-reperfusion injury by short hairpin RNA of endothelin A receptor in a rat model. *Exp Biol Med* 2012; 1:894-902.