

## The Role of Type IV Collagen in Developing Lens in Mouse Fetuses

\*<sup>1</sup>Mohammad Reza Nikravesht, <sup>1</sup> Mehdi Jalali, <sup>2</sup>Abbas Ali Moeen, <sup>3</sup>Mohammad Hassan Karimfar, <sup>4</sup>Shahin Saeidi Nejat, <sup>1</sup>Shabnam Mohammadi, <sup>5</sup>Houshang Rafighdoost

### Abstract

#### Objective(s)

Extracellular matrix (ECM) and basement membrane (BM) play important roles in many developmental processes during development and after birth. Among the components of the BM, collagen fibers specially type IV are the most important parts. The aim of this study was to determine the time when collagen type IV appears in the BM of lens structure during mouse embryonic development.

#### Materials and Methods

In this experimental study, 22 female Balb/C mice were randomly selected and were kept under normal condition, finding vaginal plug was assumed as day zero of pregnancy. From embryonic day 10 to 20, all specimens were sacrificed by cervical dislocation and their heads were fixed, serially sectioned and immunohistochemistry study for tracing collagen type IV in lens were carried out.

#### Results

Our data revealed that collagen type IV appeared at the early stage of gestation day 12 in BM of anterior epithelial lens cells and the amount of this protein gradually increased until days 15-17 in ECM and posterior capsule epithelium. After this period, severe reaction was not observed in any part of the lens.

#### Conclusion

These findings establish the important role of collagen IV in developing optic cup and any changes during critical period of pregnancy may be result in severe visual system defect

**Keywords:** Basement membrane, Collagen IV, Lens capsul

---

1- Department of Anatomy and Cell Biology, School of Medicine, Mashhad University of Medical Sciences, Mashhad, Iran

\* Corresponding Author: Tel: +98-9153114419; email:nikravesht@hotmail.com

2- Department of Anatomy, School of Medicine, Zabol University of Medical Sciences, Zabol, Iran

3-Department of Anatomy, School of Medicine, Qazvin University of Medical Sciences, Qazvin, Iran

4- School of Health, Mashhad University of Medical Sciences, Mashhad, Iran

5- Department of Anatomy, School of Medicine, Zahedan University of Medical Sciences, Zahedan, Iran

## Introduction

Lens is a transparent and flexible component of optic system which develops along with the other parts of the eyeball. In addition, it not only directs light into the environment of visual system but also it can be of prime importance in accommodation. The presence of elastic compositions in early stages of lens development helps accommodate lens capsule to physical characteristics such as strength, thinness and recoil (1). The previous studies show that collagen type IV is a major protein of the lens structure consisting of subunits  $\alpha_1$ - $\alpha_6$ . The chains  $\alpha_3$ ,  $\alpha_4$ ,  $\alpha_5$  are cross linked with each other during lens development and provide the strength required to accommodative force (2). Hence, considering that sufficient appearance of collagen guarantees proper function of the lens (3), one can conclude that in the process of natural development the lenses are more flexible in newborns than adults. This causes the accommodation and transmission of light to be more facilitative in newborns than grown-ups who have missed their accommodation or suffer from diseases such as cataract (4). Researches have shown that defect in collagen type IV expression can cause some congenital defects of optic system such as Alport syndrome (5, 6). In this case, although complex of abnormalities such as macula defect or detachment of the retina appears, vision defects such as conical anterior and posterior in lens capsule are caused (7). The absence of collagen subunits  $\alpha_3$ ,  $\alpha_4$ ,  $\alpha_5$  causes not only deformation of lens but also fragility and rupture of the capsule (8). This is one of the most important processes related to Alport syndrome (9). Based on different studies, various types of proteins are comprised in lens capsule structure such as entactin/nidogen, laminin, heparin sulfate, glycoproteins and collagen type XVIII. Although we should not ignore the structural role of lens proteins, collagen type IV is the most abundant type of collagen in lens and plays a critical role in lens development (10). It consists of triple helix structure, known as protomers, each of which forms tropocollagen (11). The helix consists of six subunits; each is expressed by a separate

gene (12). Mutation in any of the genes can result in defect of collagen synthesis and bring about a change in components of eye structures. Therefore, it is necessary to investigate its formation and structural molecule during lens development and its association with ocular defects. The present study has investigated the collagen type IV distribution and expression patterns during lens development.

## Materials and Methods

Twenty two pregnant female Balb/c mice of 35 g body weight were obtained from animal house of Mashhad University of medical sciences, the environmental conditions were 23-25 °C, relative humidity 50-55%, 12 hr light-dark cycle (light on at 6.00 am). Female mice were mated with males of the same strains (two females and one male) overnight and examined the next morning for vaginal plug. Females with sperm-positive smears or vaginal plug were designated as day zero of pregnancy. Two Pregnant mice from gestational days E<sub>10</sub> to E<sub>20</sub> were anesthetized with chloroform and perfused transcardially with formaldehyde 10% and the head of fetuses were removed and fixed for 24 hr at room temperature in the same fixative. The head of fetuses routinely processed and embedded in paraffin. Then eight-micron sagittal sections were carried out serially. Interval sections were one from each ten. Sections were stained with cresyl violet or incubated with monoclonal antibody (anti-collagen IV/ Dako Co.).

### *Immunohistochemistry study*

The Avidin-Biotin peroxidase procedure was used for immunohistochemistry study. Sections deparaffinized, rehydrated and washed twice for 5 min in 0.05 Tris buffer containing 1.5% NaCl, pH 7.4. For blocking nonspecific antibody, sections were preincubated in 0.3% Triton X-100 in TB-NaCl followed by 5% goat serum for 2-3 hr. Then sections were reacted for 12-24 hr at 4 °C with primary antibody (anti-collagen IV) diluted 1:250 in TB-NaCl with 0.3% Triton and 2% serum. Tissues were washed

## Type IV Collagen in Developing Lens

with TB-NaCl for three times, each time for 10 min and incubated for 2 hr in biotinylated goat anti-rabbit IgG (1:400 in TB-NaCl). After three further rinses, each for 1 hr, endogenous peroxidase activity was blocked by incubating in 0.03% H<sub>2</sub>O<sub>2</sub> in methanol for 30 min. Tissues were incubated for 2 hr in 1:100 avidin-biotinylated horseradish peroxidase complex. Then they were washed three times, each time for 30 min in TB-NaCl and finally reacted with 0.03% solution of 3,3-diaminobenzidine tetrahydrochloride containing 0.03% H<sub>2</sub>O<sub>2</sub> for 10-15 min. Tissues were washed and were lightly counterstained with hematoxylin. Subsequently, they were washed, air-dried, dehydrated, and then mounted in PBS glycerol. Photographs were taken by a bh<sub>2</sub> Olympus light microscope and collagen IV reaction in lens components in each of embryonic days was evaluated.

### Statistical analysis

The data were analyzed by using SPSS software and Kruskal Wallis and Mann-Whitney tests. *P*-values < 0.05 was considered as significant.

### Results

Our data indicated that primary lens was visible in anterior capsule epithelium of optic cup as an undifferentiated cellular mass on day

11 of gestation (Figure 1a). On day 11, although anterior part of the lens is formed, collagen indicated no reaction in basement membrane (Figure 1b). On day 12, most of the primordial lens cells were degenerated and replaced with lens matrix. Based on our finding, collagen IV appeared at the early stage of embryonic day 12 during critical period of the developing lens. In addition, this study indicated high levels of collagen IV expression at the BM of anterior epithelial cells of the lens during early development of mouse lens (E-15 to E-17), while anterior epithelial capsule was growing. After that, the structure of BM was completed in this area and collagen IV became stable after this period. From day 14, intensity of collagen expression in lens significantly increased compared to embryonic day 11. On day 15 of gestation, the reaction of anterior epithelium remarkably increased and expanded into the lens nucleus but decreased in this region and there was weak reaction in posterior lens capsule (Figure 1c and 1d). On day 17 of gestation, collagen fibers were expanded into adjacent lens nucleus (table 1). In this case, although posterior lens capsule was labeled with antibody against collagen, narrow band of posterior capsule epithelium indicated no reaction except for the remains of primordial cells in this region (Figure 1e and 1f).

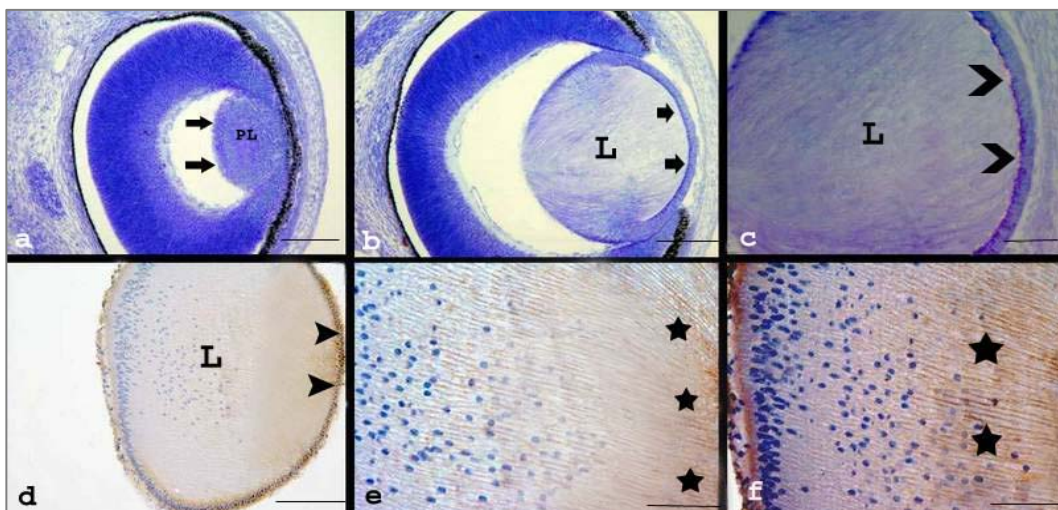


Figure 1. Images a-f showing sections through the eyeball through days 10-17 of gestation respectively, a: on day 11th , primary lens (pl) b: on day 12th, the lens matrix (L) with distinct anterior capsule (arrows). c: day 13, weakly reaction in basement membrane of anterior epithelium (bifurcate arrows). d: section through lens on day 15. Anterior epithelium with remarkable reaction (arrows) and e: part of lens on day 15 of gestation with higher magnification which clearly showed collagen reaction in lens nucleus (asterisks). f: section through lens on day 17 of gestation when collagen fibers (asterisks) were expanded into the adjacent posterior part of lens nucleus (scale bar=100  $\mu$ m, Haematoxylin counterstained,).

Table 1. Lens components collagen IV reaction during embryonic development

Day embryo	Anterior epithelium	Lens nucleus	Anterior pole	Posterior pole
10	-	-	-	-
11	-	-	-	-
12	(+)	-	-	-
14	(+++)	(+)	(++)	(+)
15	(++++)	(+++)	(++++)	(++)
17	(++++)	(++++)	(++++)	(++)

This gradation was scored ranging from negative to 4 positive in conformity with the severity of reaction from negative, weak, moderate, strong and very strong.

## Discussion

Basement membranes are specialized extracellular matrices consisting of tissue-specific organizations of multiple matrix molecules and serve as structural barriers as well as substrates for cellular interactions. Collagen fibers specially type IV are the most important part of this area. Our immunohistochemistry studies showed that there is no reaction of collagen type IV until day 12 of gestation. Another investigation also revealed that first collagen IV expression in mouse was detectable in lens capsule as early as embryonic day 11.5 (13, 14). The appearance of first signals of collagen type IV in basement membrane of the anterior capsule represents an important role in lens development because anterior capsule consists of specialized basement membrane to which epithelial cells bind (15). As the structural compositions of the lens are completed, the specific role of collagen becomes distinguished in this part of visual system. Since the marginal zone of capsule binds to zonules which connects capsule to ciliary body using stable and thin fibers (16), the strength force diffuses to the lens surface. So compositions such as collagen are required to provide stability and flexibility (17). Besides serving structural role, collagen type IV may transmit signals for natural eye development (18). In other words, subunits of collagen type IV can bind to cell-surface and intracellular receptors and affect compositions of the lens matrix (19). Checking out the emergence of collagen in later days, especially day 15, showed that its density significantly increased from anterior to posterior capsule epithelium of the lens. This density is in its maximum level on day 17 of gestation when the capsule as well as structural composition of the lens is full of collagen. Although collagen indicated

poor reaction in matrix of posterior capsule epithelium, this reaction was very weak while compared to the other parts of the lens. Here, the distribution pattern did not show distinguished change in the following days. Therefore, to have better understanding of formation, development and the role of collagen type IV in accommodation, it is necessary to obtain information on the appearance and distribution of collagen type IV and its alterations (20). In other words, the appearance of collagen type IV on day 12 and its increase till embryonic day 17 is an index of developmental changes in optic system. So, while lens development completes, the collagen synthesis stops. During these stages, the cell mass known as lens precursor disappears gradually and is replaced with macromolecules such as collagen type IV (21). Similar immunohistochemistry studies on subunits of collagen (IV)  $\alpha_1$ ,  $\alpha_6$  in pre- and postnatal stages showed that first collagen is formed in anterior and posterior capsule epithelium and then is expanded to the other parts of lens until day 16.5 of gestation (22).

The results of this study showed that density of collagen in posterior capsule epithelium is lower in contrast to other parts of the lens except for the patchy distribution of embryonic cells observed in this region. Although these cells disappear gradually to provide transparency of the lens in early stages of postnatal, the collagen causes induction effects on apoptosis. However, weak reaction of collagen in posterior capsule epithelium didn't accelerate the apoptosis in embryonic period. In diseases such as Alport syndrome changes in collagen expression result in ocular defects such as cataract. These changes can result in a dense collagen in the aged and diabetic individuals as well as cataract.

### Acknowledgment

This work was supported by research grant Number 87040 from office of Vice-Chancellor for Research Affairs of Zabol University of Medical Sciences and office of Vice-Chancellor for Research Affairs of Mashhad

University of Medical Sciences and the authors wish to thank them for their financial support. We also wish to thank Mrs. Motejadded for her excellent technical assistance.

### References

1. Frost MR, Norton TT. Differential protein expression in tree shrew sclera during development of lens-induced myopia and recovery. *Mol Vis* 2007; 13:1580-1588.
2. Biro Z, Kereskai L, Tsorbatzoglou A, Vasavada AR, Berta A. Histological examination of primary posterior capsule plaques. *J Cataract Refract Surg* 2007; 33:439-442.
3. Johar K, Vasavada AR, Tatsumi K, Dholakia S, Nihalani B, Rao SS. Anterior capsular plaque in congenital cataract: occurrence, morphology, immunofluorescence, and ultrastructure. *Invest Ophthalmol Vis Sci* 2007; 48:4209-4214.
4. McMonnies CW, Schief WK. Biomechanically coupled curvature transfer in normal and keratoconus corneal collagen. *Eye Contact Lens* 2006; 32:51-62.
5. Ohkubo S, Takeda H, Higashide T, Ito M, Sakurai M, Shirao Y, *et al.* Immunohistochemical and molecular genetic evidence for type IV collagen alpha5 chain abnormality in the anterior lenticonus associated with Alport syndrome. *Arch Ophthalmol* 2003; 121:846-850.
6. McCarthy PA, Maino DM. Alport syndrome: a review. *Clin Eye Vis Care* 2000; 2:139-150.
7. Colitz CM, Malarkey D, Dykstra MJ, McGahan MC, Davidson MG. Histologic and immunohistochemical characterization of lens capsular plaques in dogs with cataracts. *Am J Vet Res* 2000; 61:139-143.
8. Kelley PB, Sado Y, Duncan MK. Collagen IV in the developing lens capsule. *Matrix Biol* 2002; 21:415-423.
9. Colville DJ, Savige J. Alport syndrome. A review of the ocular manifestations. *Ophthalmic Genet* 1997; 18:161-173.
10. Mishra G, Das GB, Behera HN. Possible role of lens collagen in cataractogenesis. *Indian J Ophthalmol* 1997; 45:227-231.
11. Olivero DK, Furcht LT. Type IV collagen, laminin, and fibronectin promote the adhesion and migration of rabbit lens epithelial cells in vitro. *Invest Ophthalmol Vis Sci* 1993; 34:2825-2834.
12. Shahan T, Grant D, Tootell M, Ziaie Z, Ohno N, Mousa S, *et al.* Oncostatin, a peptide from the alpha3 chain of type IV collagen, modifies endothelial cell function and inhibits angiogenesis. *Connect Tissue Res* 2004; 45:151-163.
13. Brian PD, Melinda KD. The lens capsule. *Exp Eye Res* 2009; 88:151-164.
14. Scott JH, Paul ST. Type IV collagen: A network for development differentiation, and disease. *Adv Dev Biol* 2005; 15: 1-64.
15. Hartmann U, Sistani F, Steinhorst UH. Human and porcine anterior lens capsule as support for growing and grafting retinal pigment epithelium and iris pigment epithelium. *Graefes Arch Clin Exp Ophthalmol* 1999; 237: 940-945.
16. Saika S, Miyamoto T, Ishida I, Barbour WK, Ohnishi Y, Ooshima A. Accumulation of thrombospondin-1 in post-operative capsular fibrosis and its down-regulation in lens cells during lens fiber formation. *Exp Eye Res* 2004; 79:147-156.
17. Danielsen CC. Tensile mechanical and creep properties of Descemet's membrane and lens capsule. *Exp Eye Res* 2004; 79:343-350.
18. Fitch JM, Kidder JM, Linsenmayer TF. Cellular invasion of the chicken corneal stroma during development: regulation by multiple matrix metalloproteases and the lens. *Dev Dyn* 2005; 232:106-118.
19. Futter CE, Crowston JG, Allan BD. Interaction with collagen IV protects lens epithelial cells from Fas-dependent apoptosis by stimulating the production of soluble survival factors. *Invest Ophthalmol Vis Sci* 2005, 46:3256-3262.
20. Linnola RJ, Sund M, Ylönen R, Pihlajaniemi T. Adhesion of soluble fibronectin, vitronectin, and collagen type IV to intraocular lens materials. *J Cataract Refract Surg* 2003; 29:146-152.
21. Johnson MC, Beebe DC. Growth, synthesis and regional specialization of the embryonic chicken lens capsule. *Exp Eye Res* 1984; 38:579-592.
22. Kelley PB, Sado Y, Duncan MK. Collagen IV in the developing lens capsule. *Matrix Biol* 2002; 21:415-423.